




ARRITMIAS 2010

DUE Fernando Martín

Taller de Interpretación de Trazados en el Laboratorio de Electrofisiología

Casos clínicos interactivos
para el perfeccionamiento profesional
y formación continuada



ARRITMIAS 2010

del 7 al 9 de Abril de 2010

IX REUNIÓN ANUAL

CASO CLÍNICO

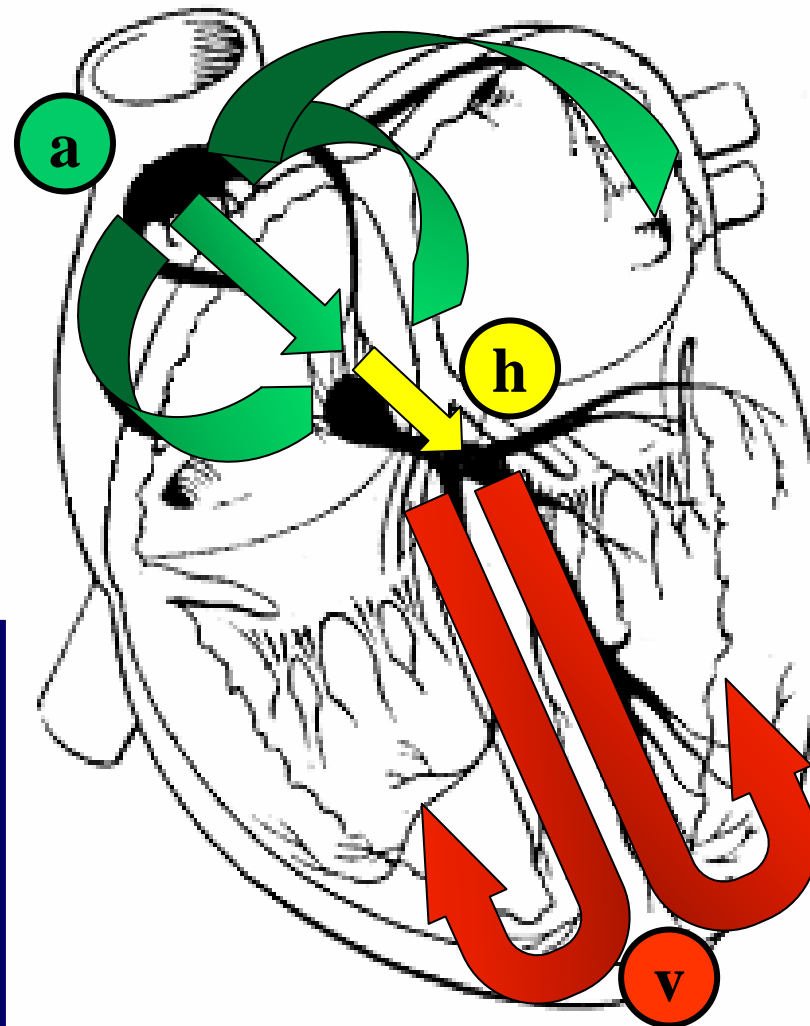
- **Varón de 38 años de edad.**
- **AP: Tabaquismo.**
- **Motivo de consulta: Palpitaciones**
- **Taquicardias desde los 16 años.**
- **EEF hace 20 años. Diagnóstico: T**
- **Tto: Manidón 120 mg / 12 h.**
- **No cardiopatía estructural.**

ARRITMIAS 2010

del 7 al 9 de Abril de 2010

IX REUNIÓN ANUAL

CASO CLÍNICO



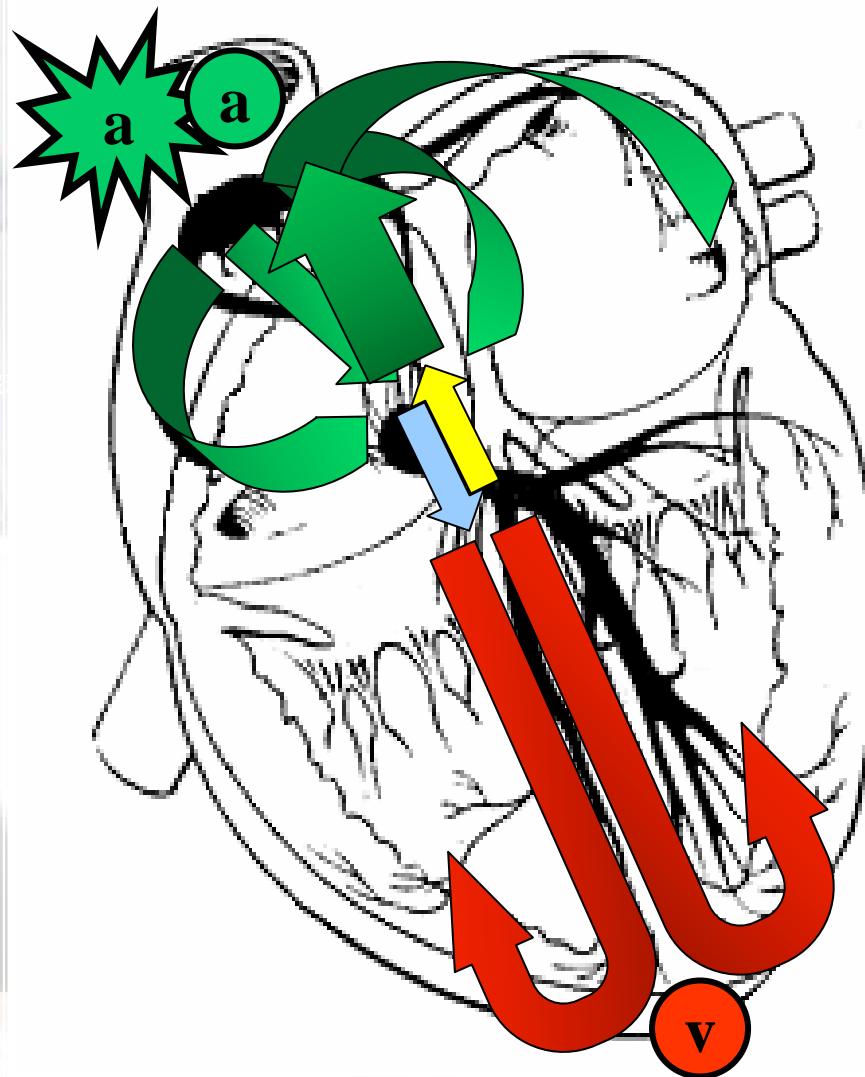



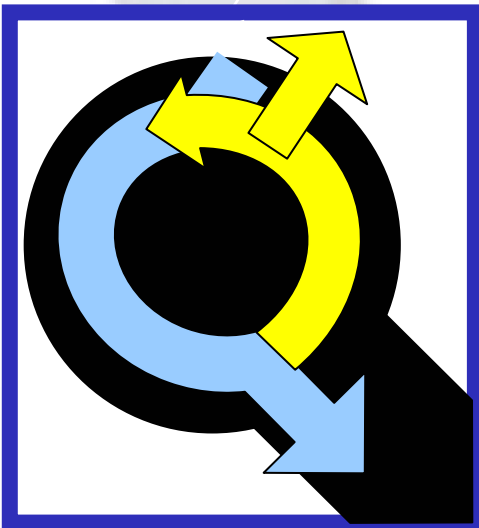
ARRITMIAS 2010

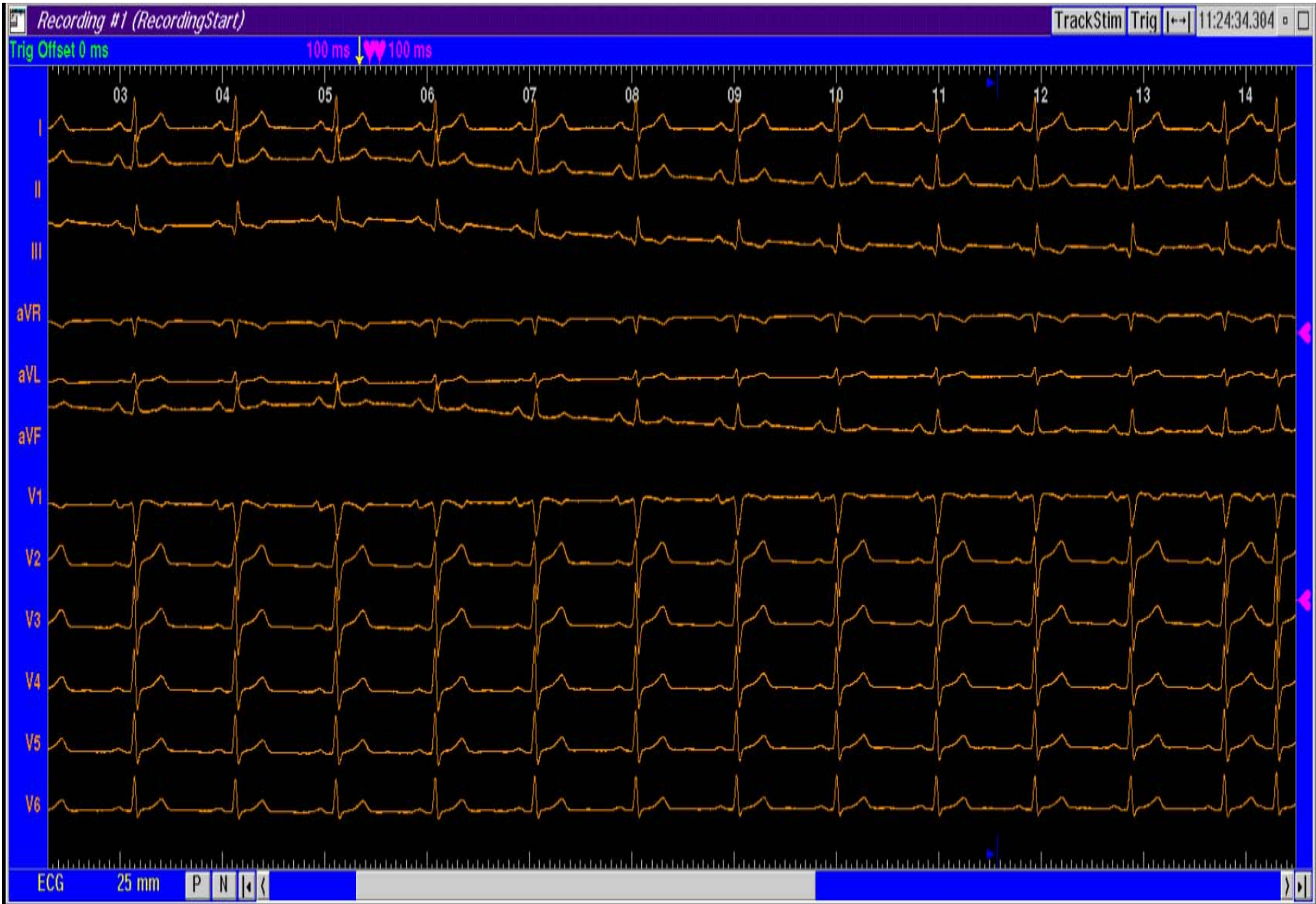del 7 al 9 de Abril de 2010

IX REUNIÓN ANUAL

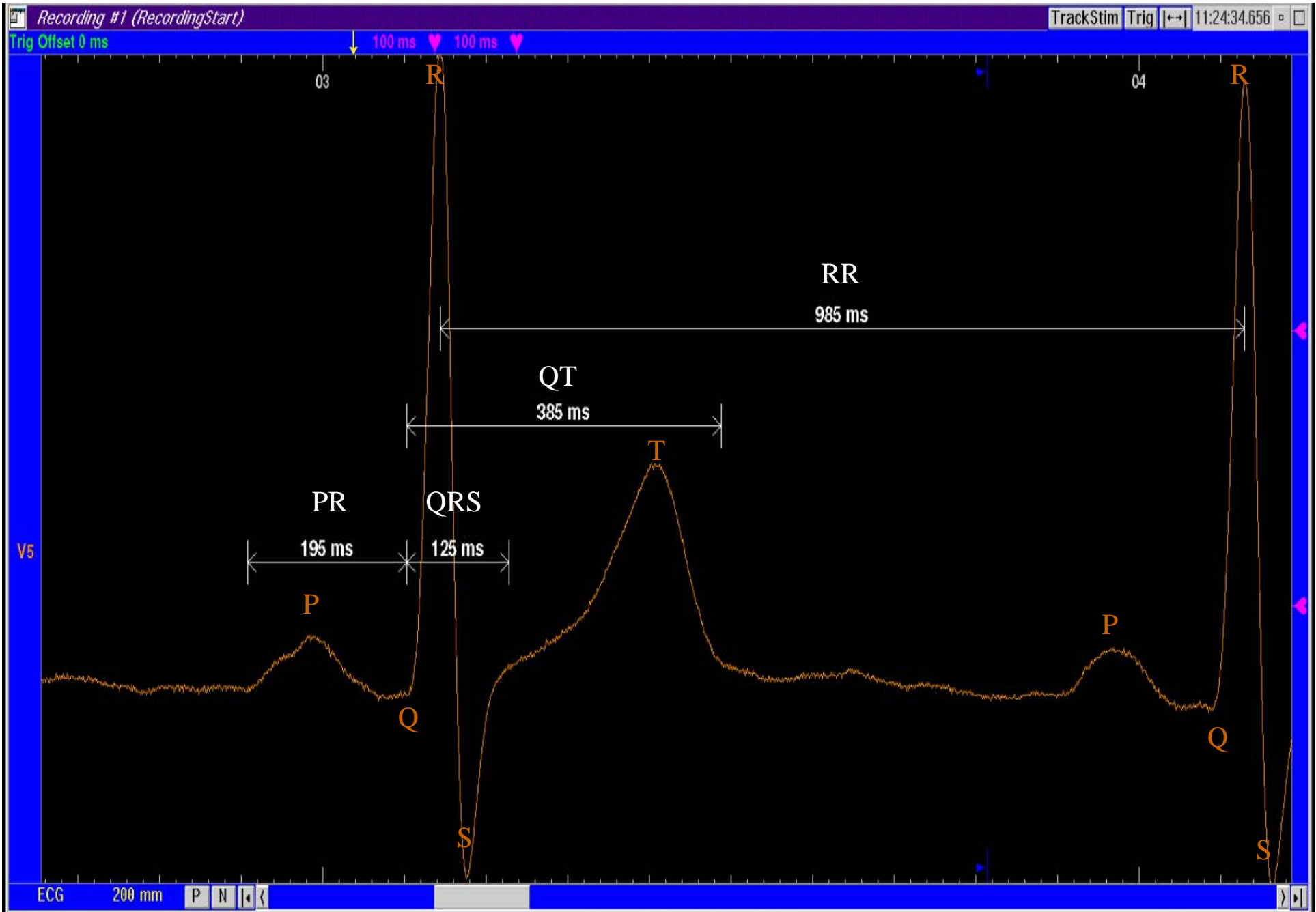
CASO CLÍNICO








ECG Basal



Intervalos de Conducción

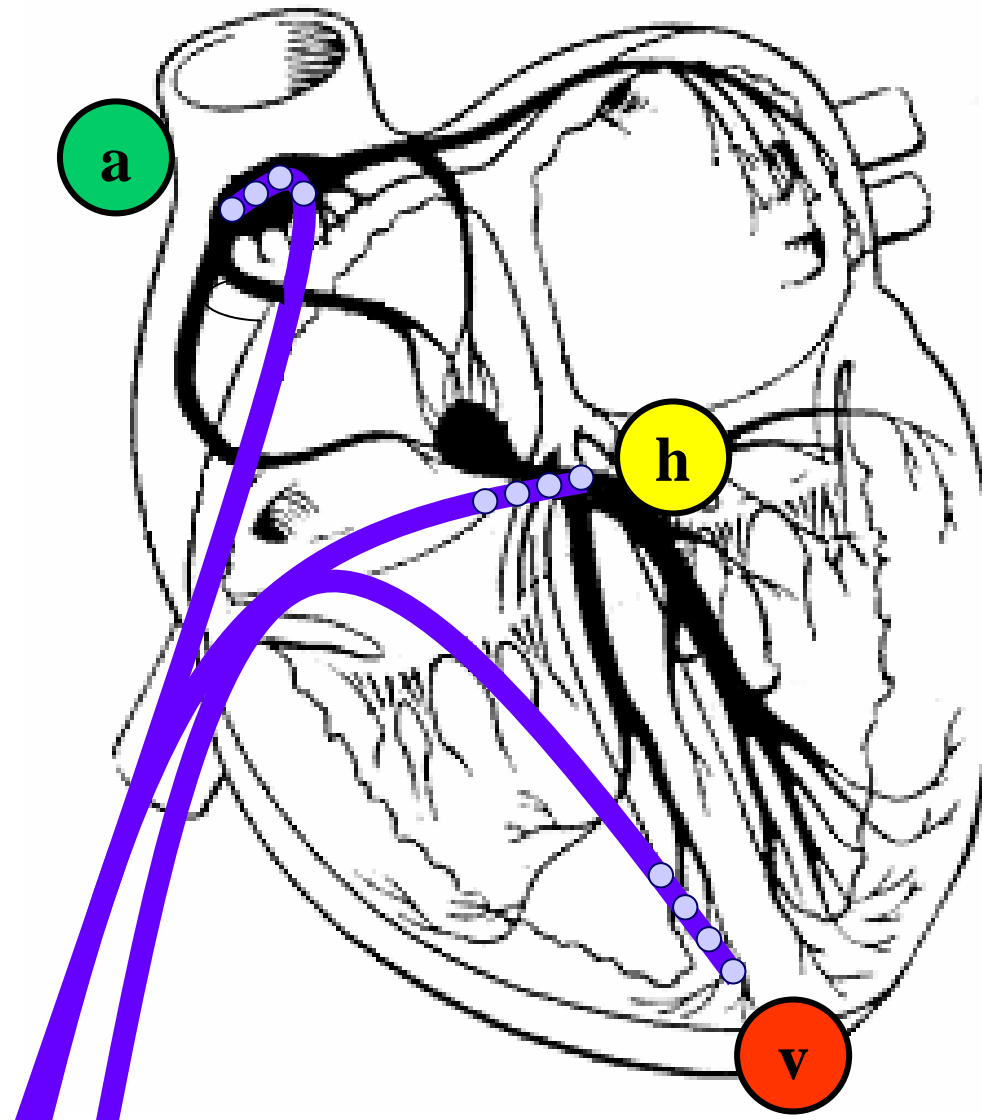


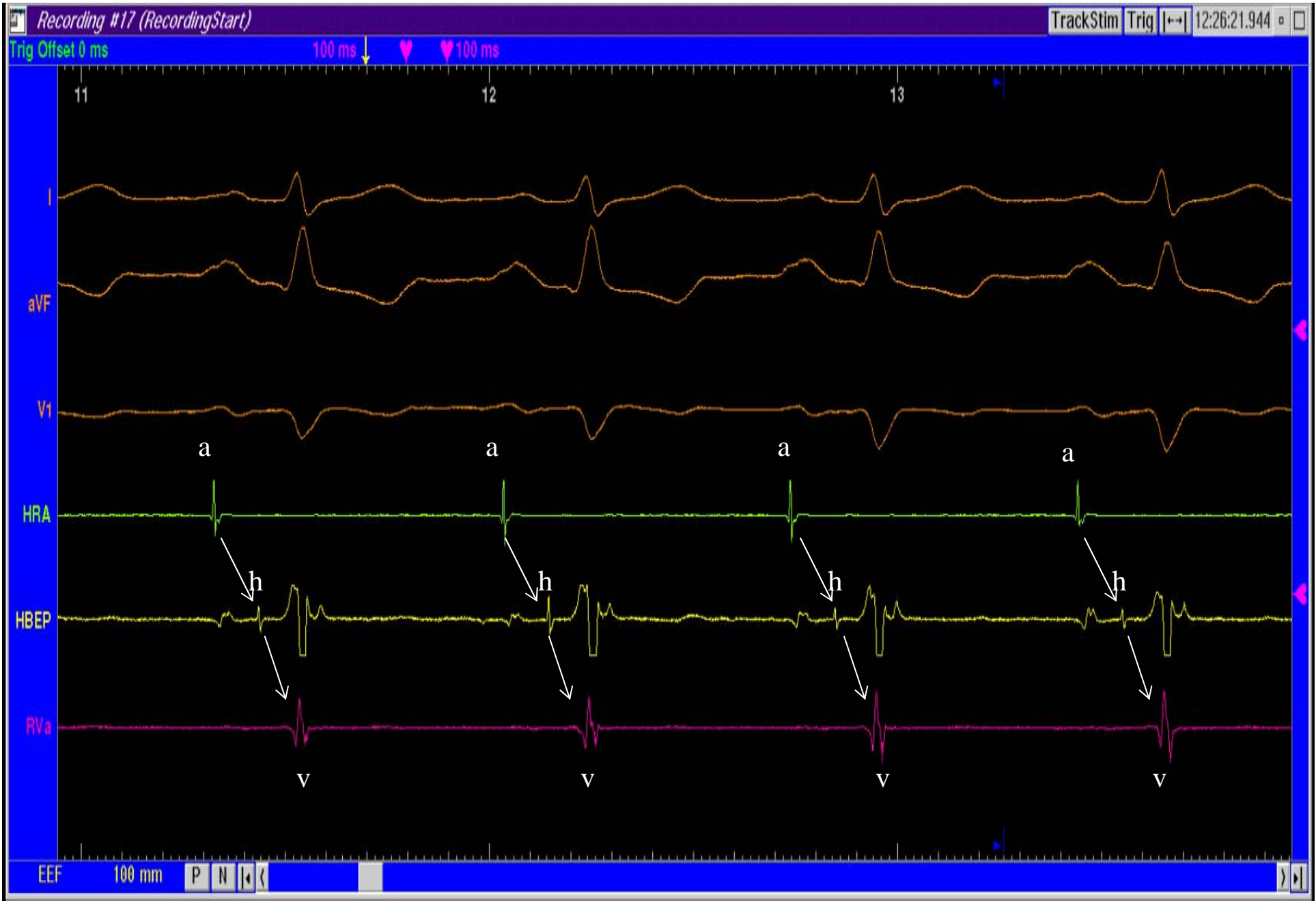ARRITMIAS 2010

del 7 al 9 de Abril de 2010

IX REUNIÓN ANUAL

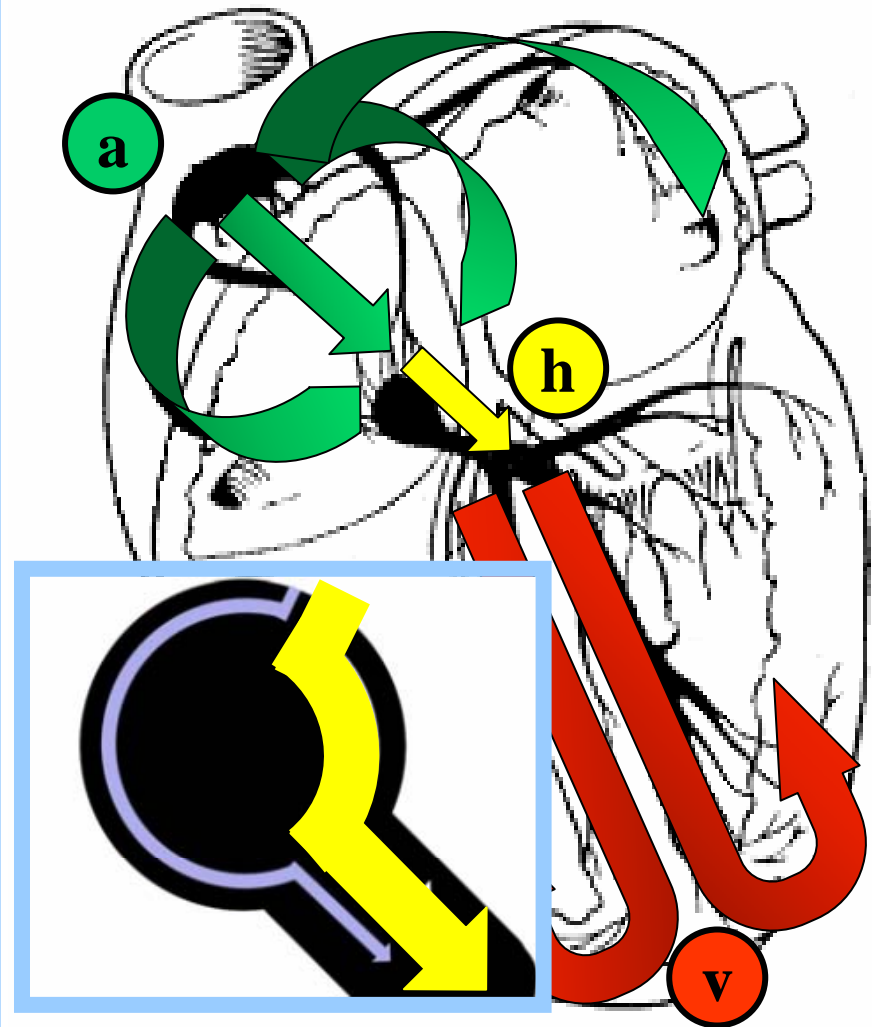

E.E.F.

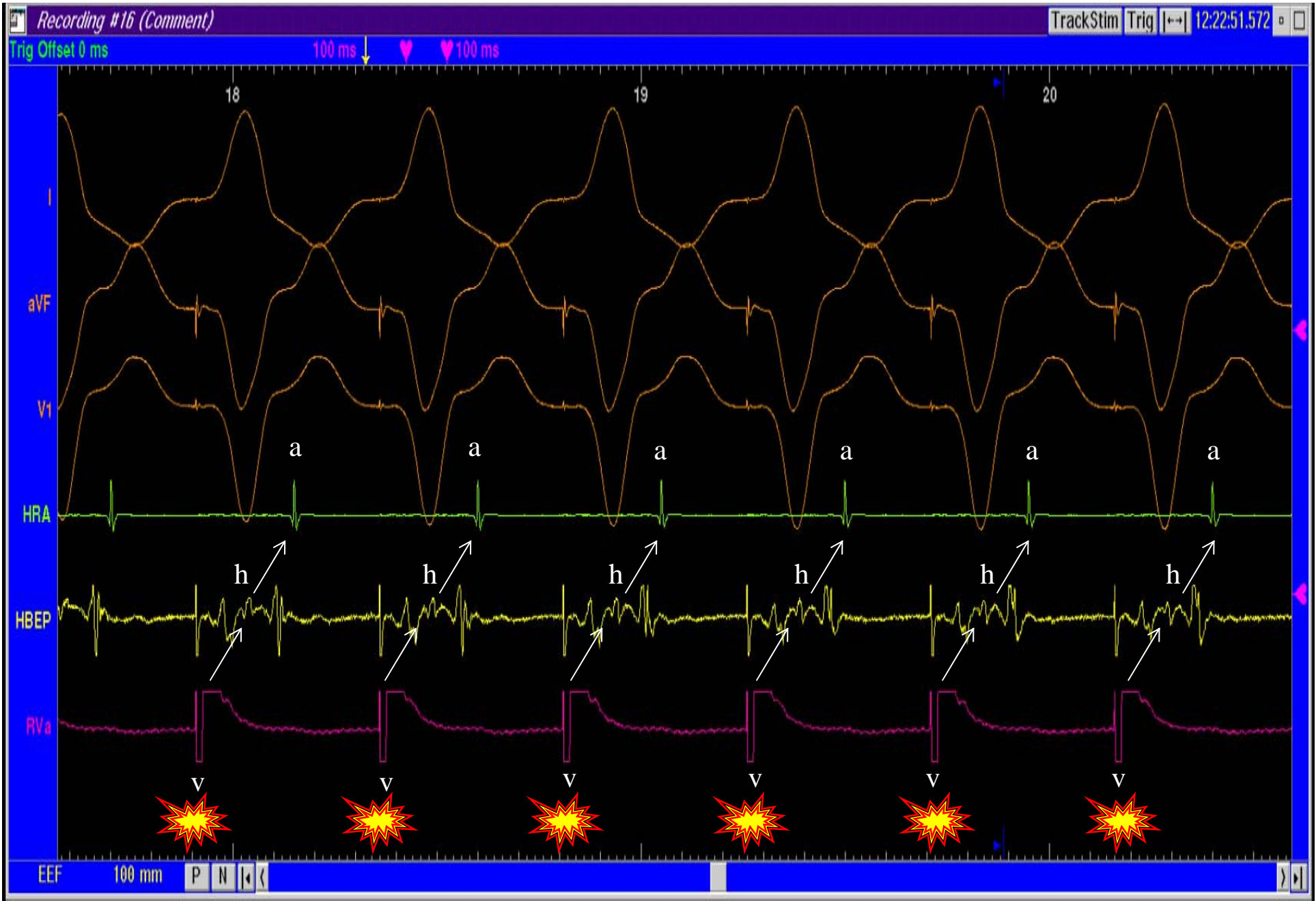




Registros Intracavitarios Basales

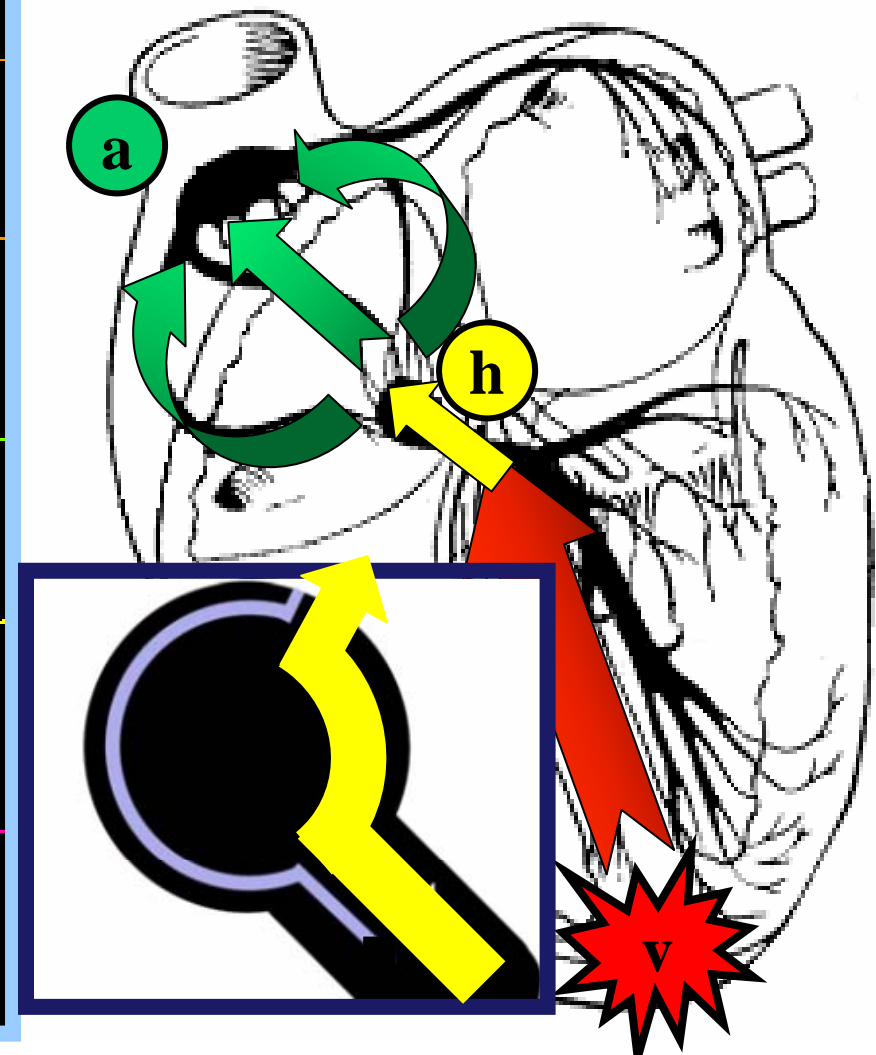
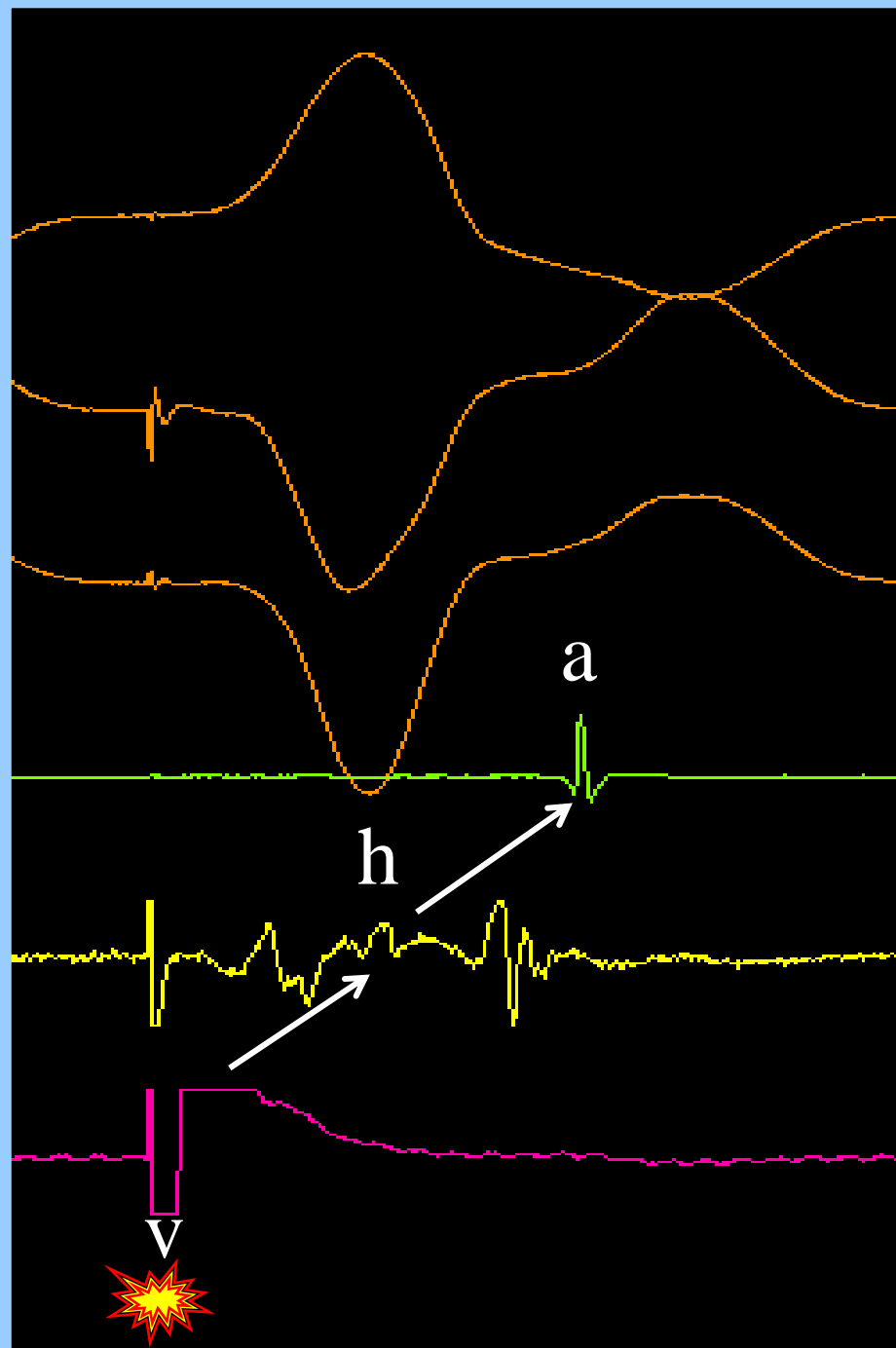
Registros Intracavitarios Basales

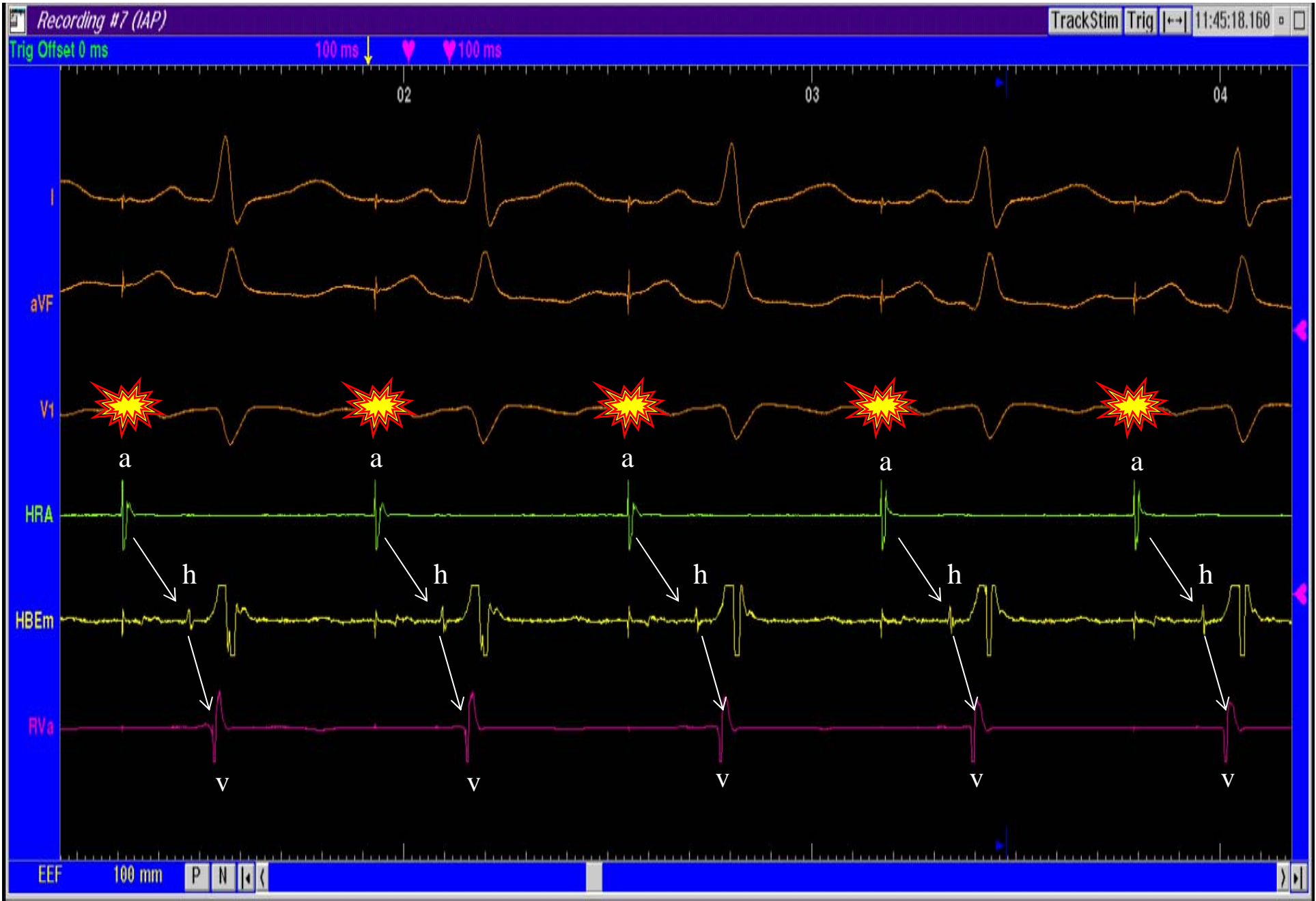




Estimulación Ventricular Continua. Conducción VA

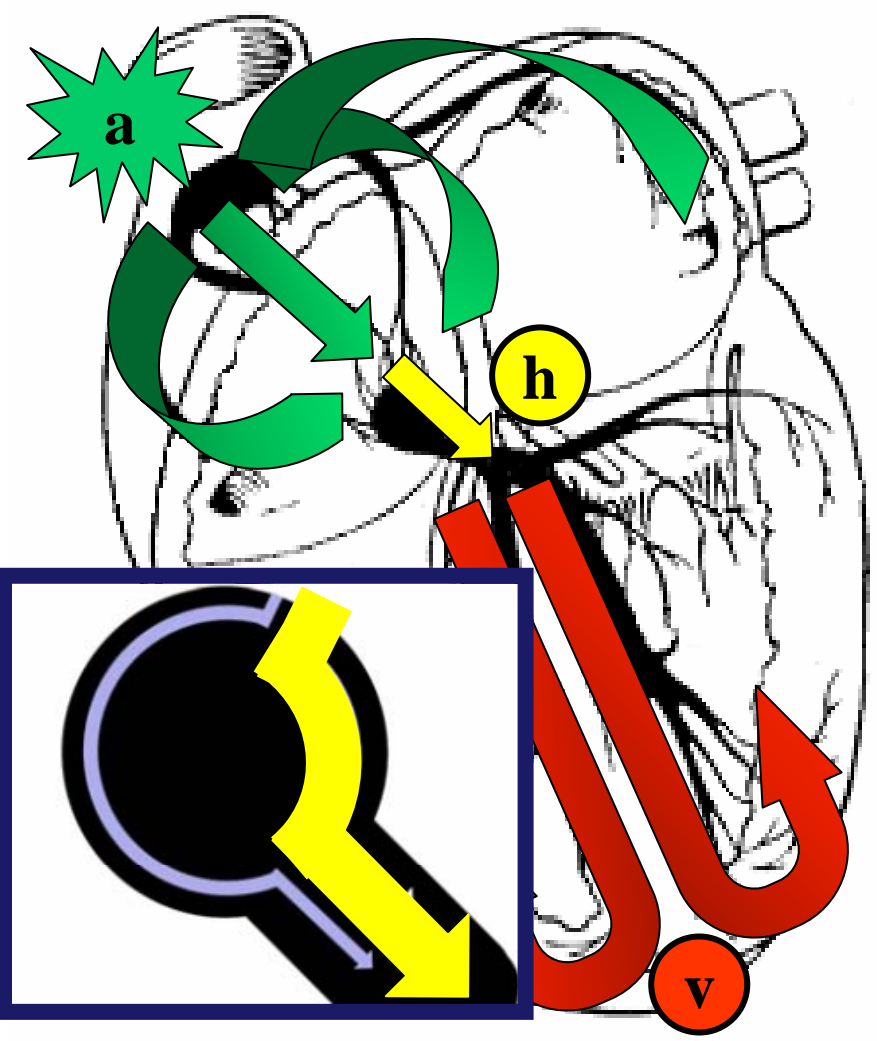
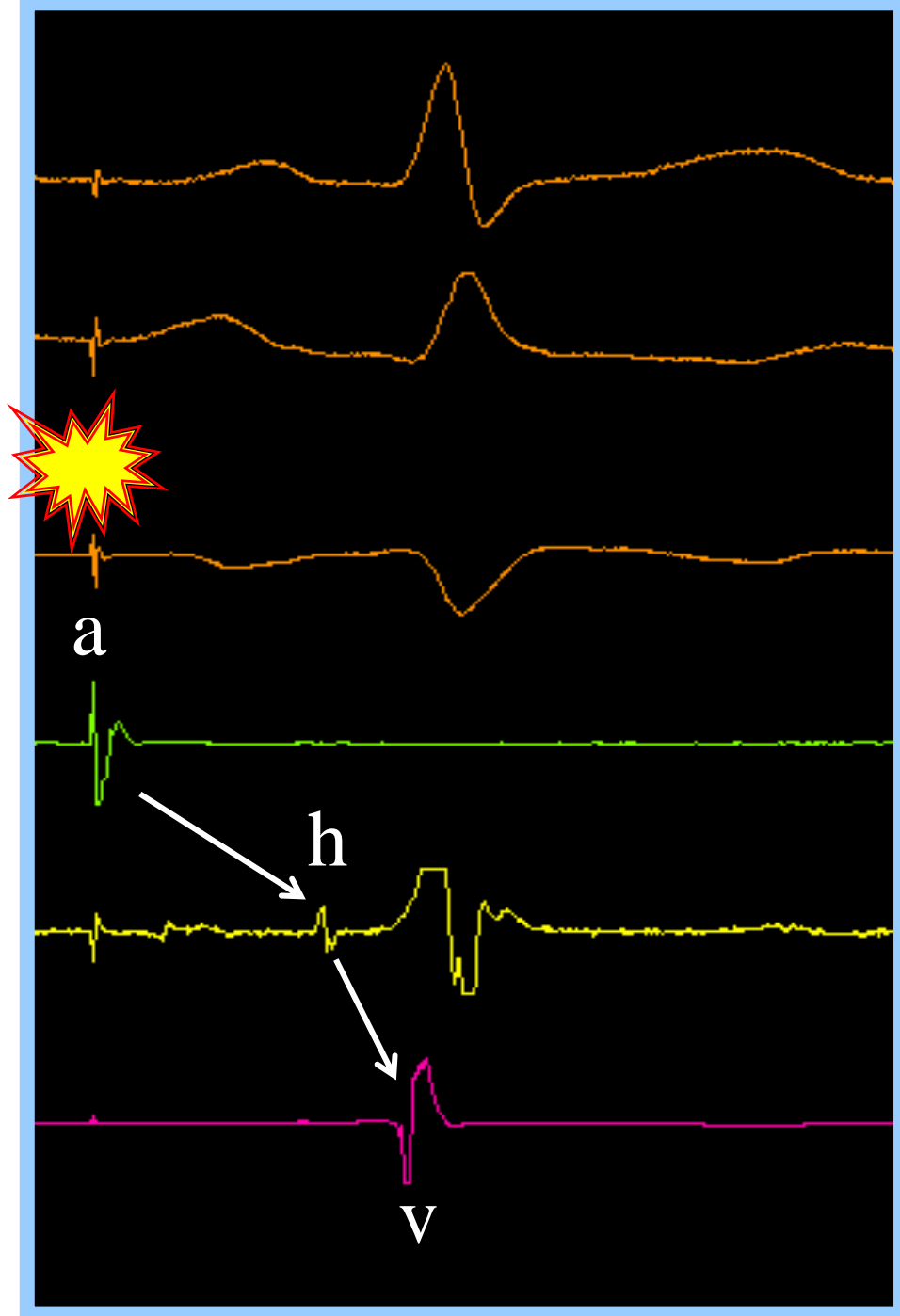
Conducción Retrógrada

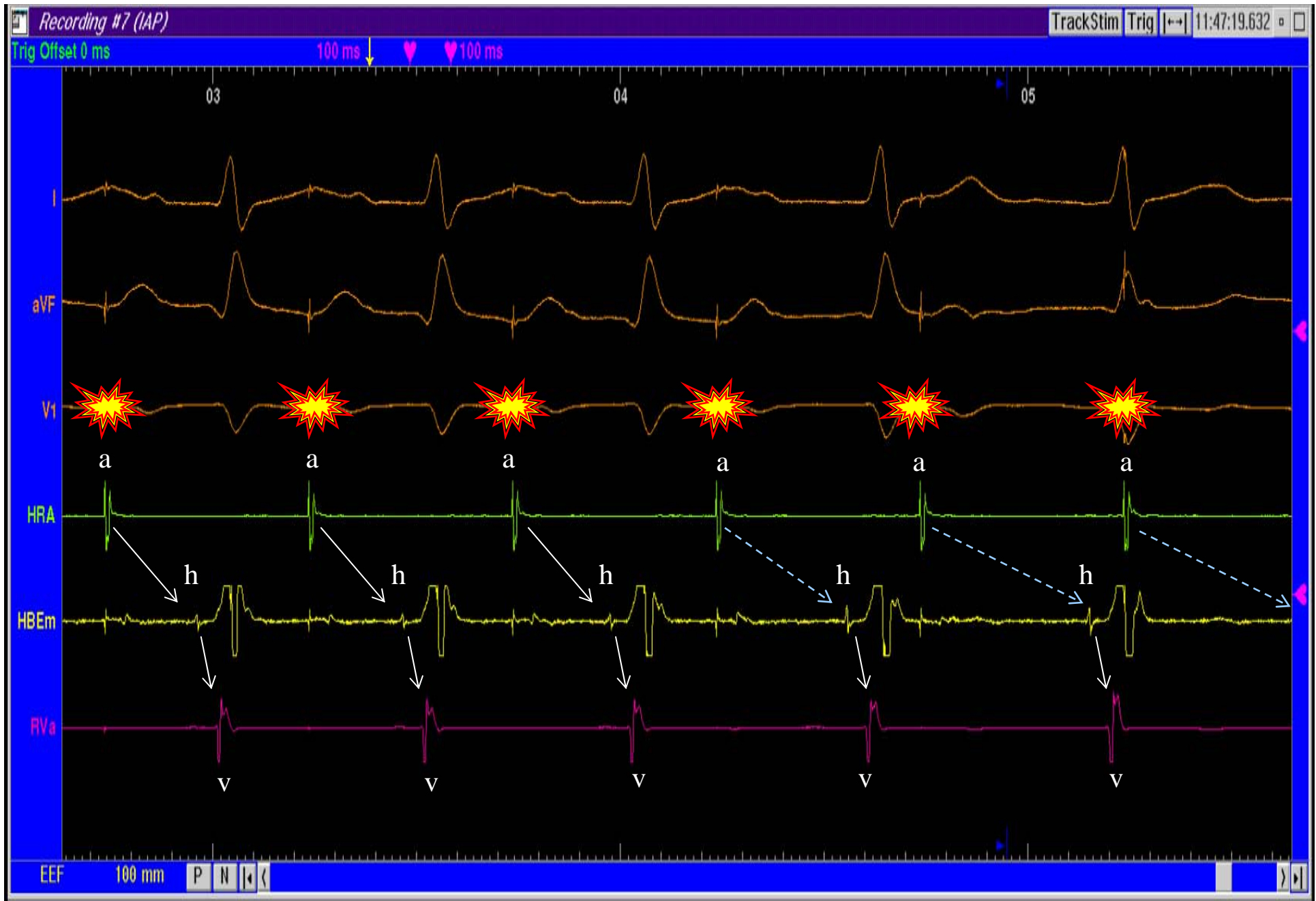




Estimulación Auricular Continua. Vía Rápida

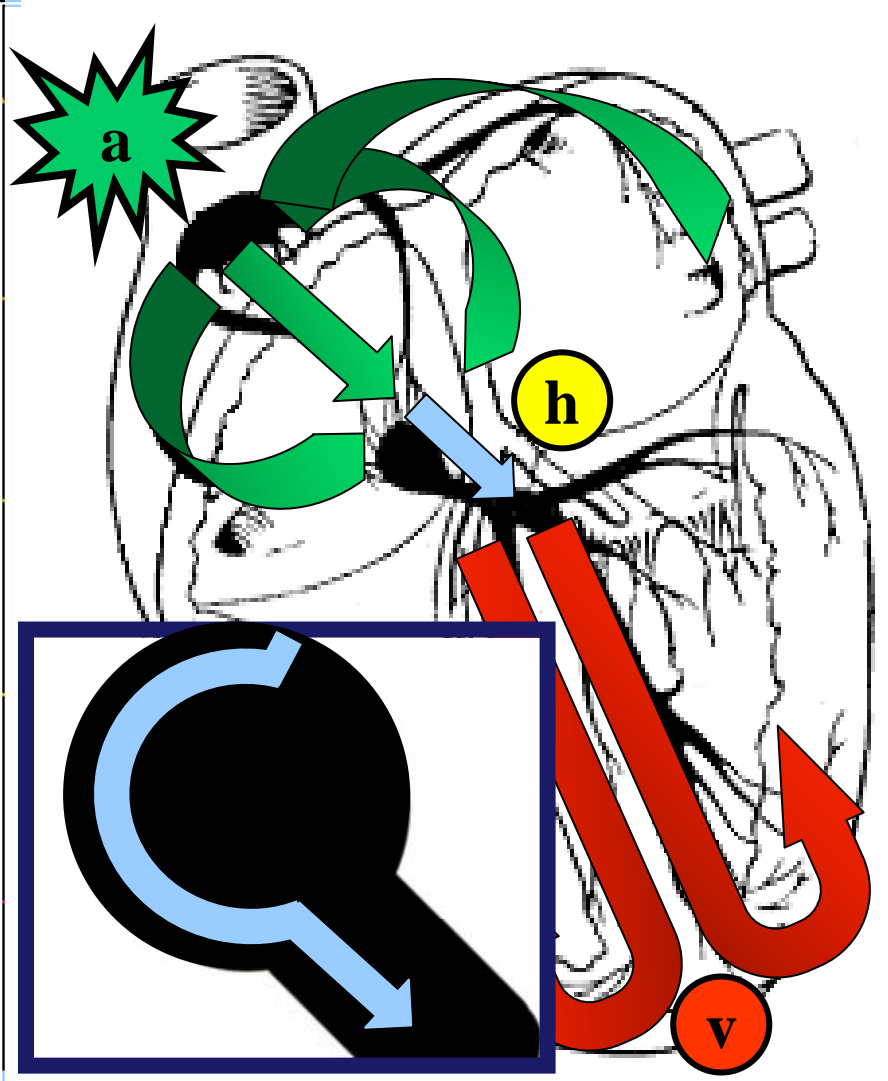
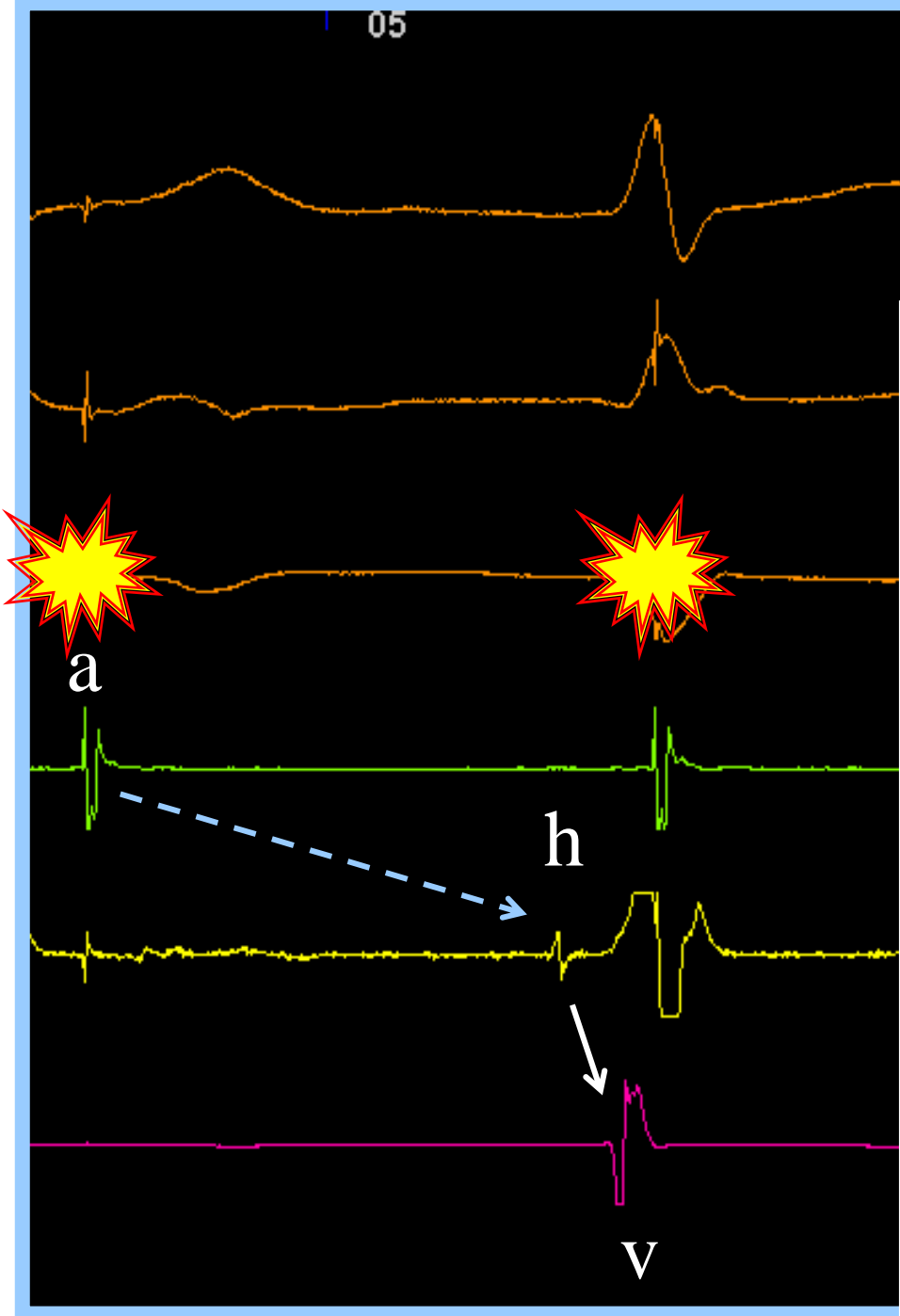
Estimulación Auricular Continua. Vía Rápida.

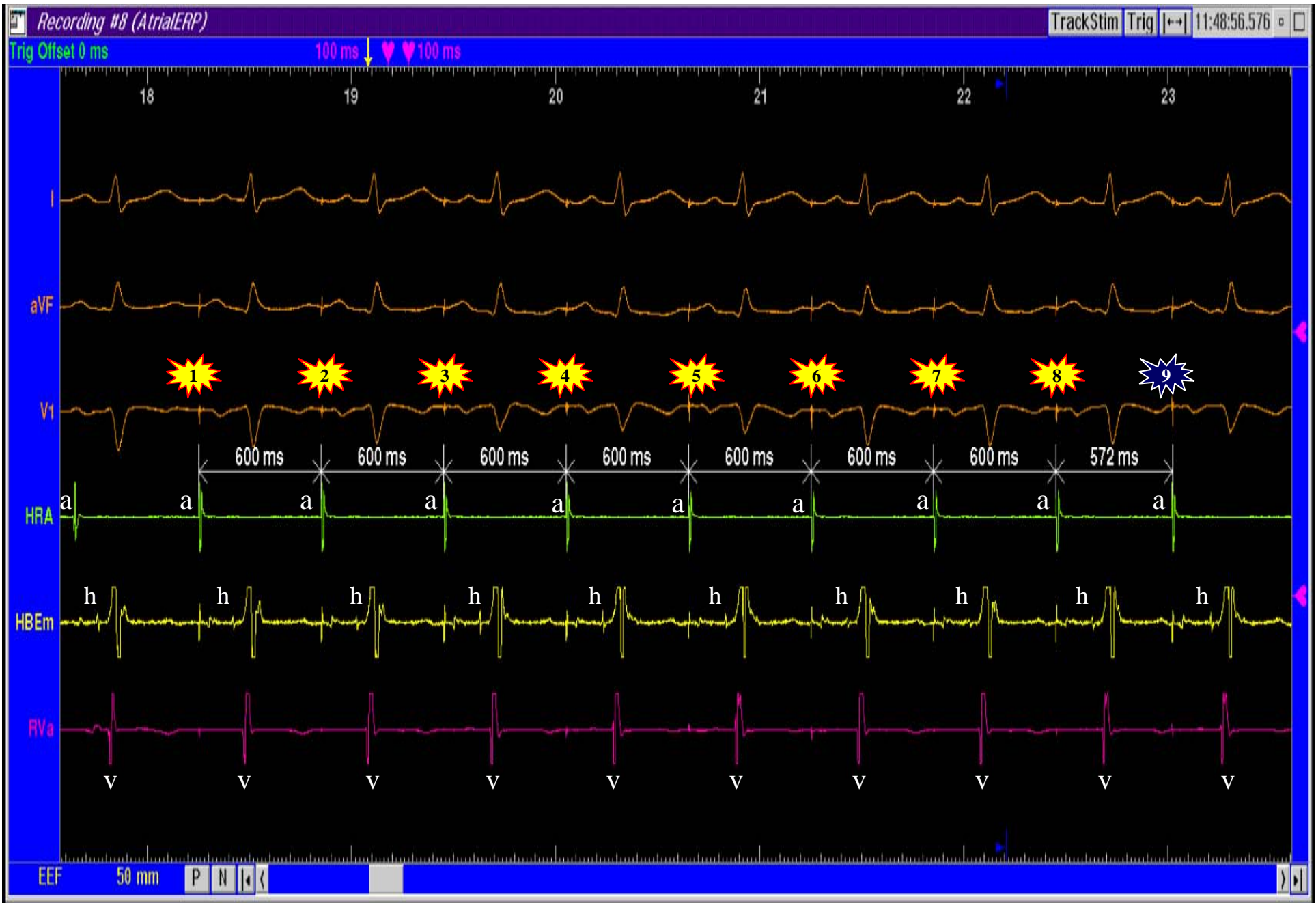



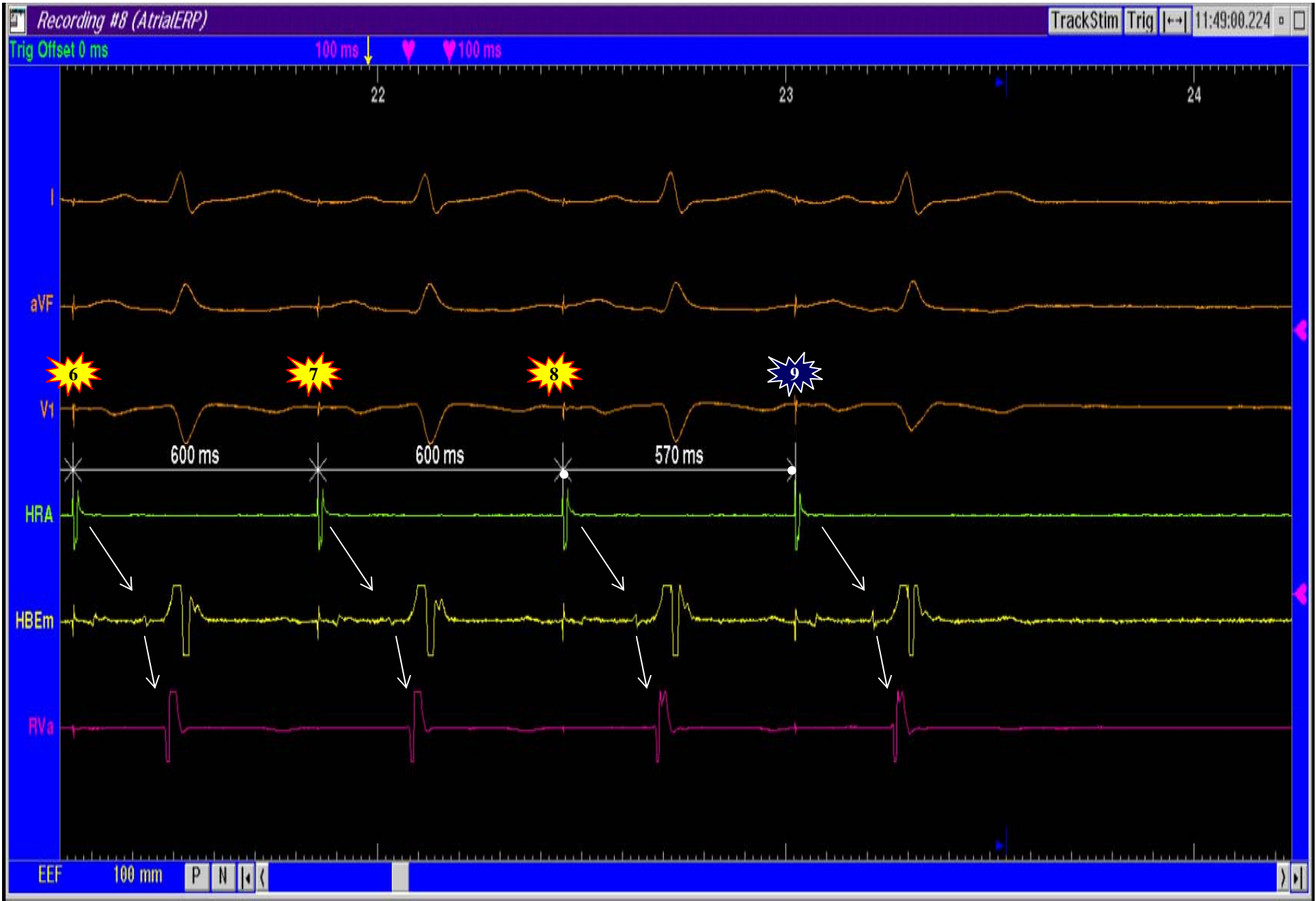
Estimulación Auricular Continua. Vía Lenta

Estimulación Auricular Continua. Vía Lenta.



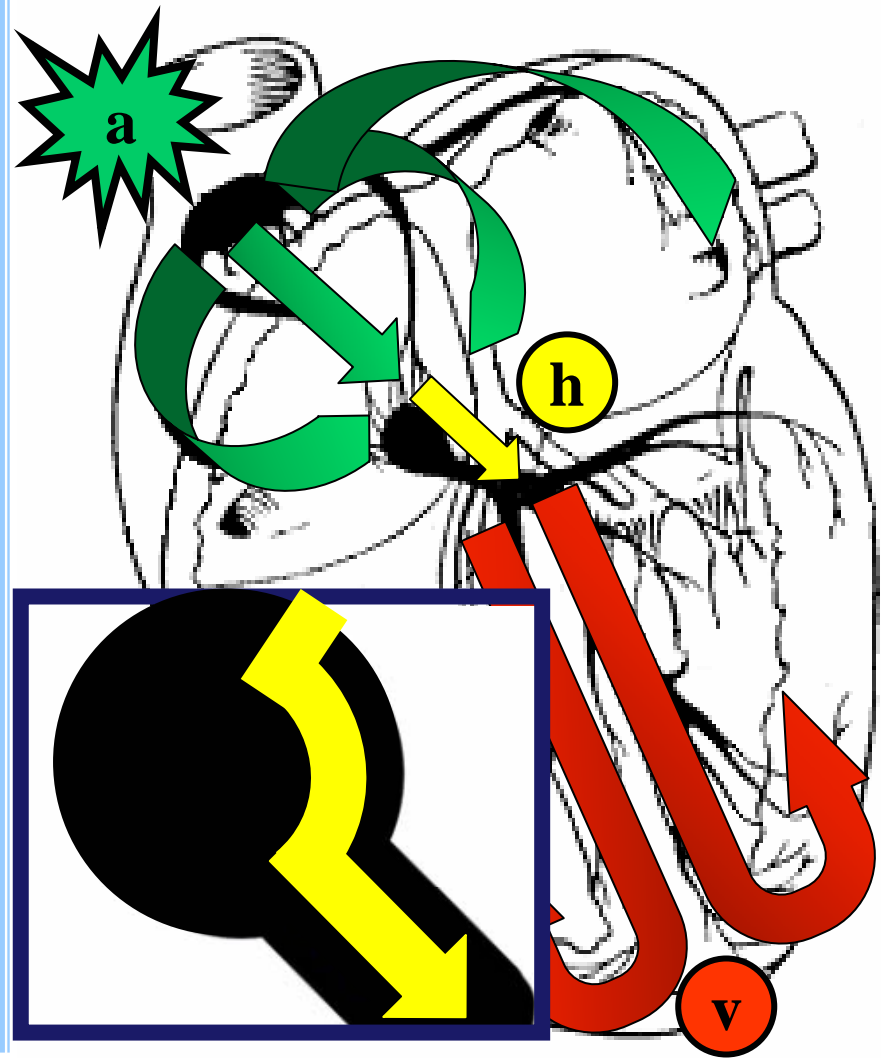
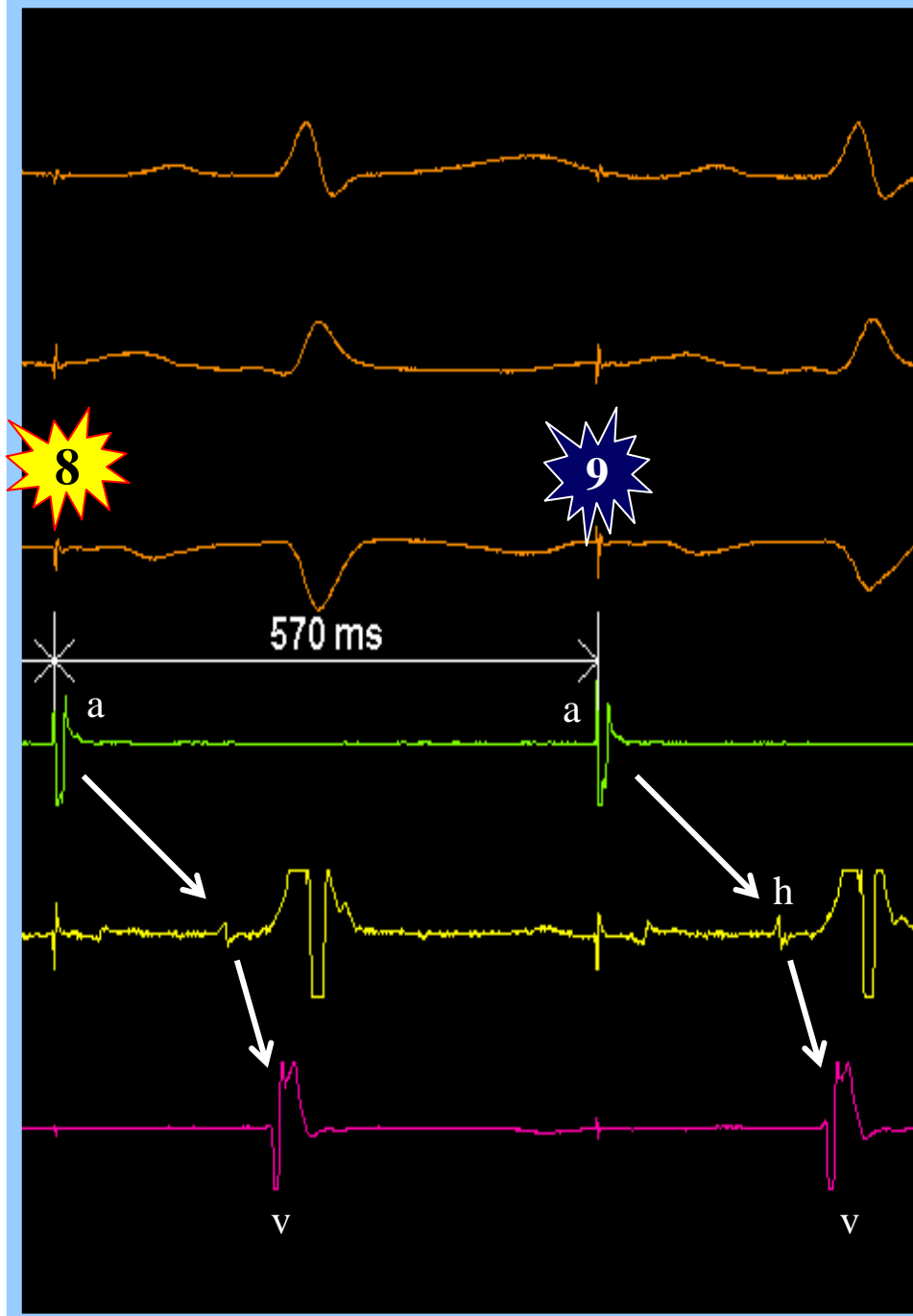


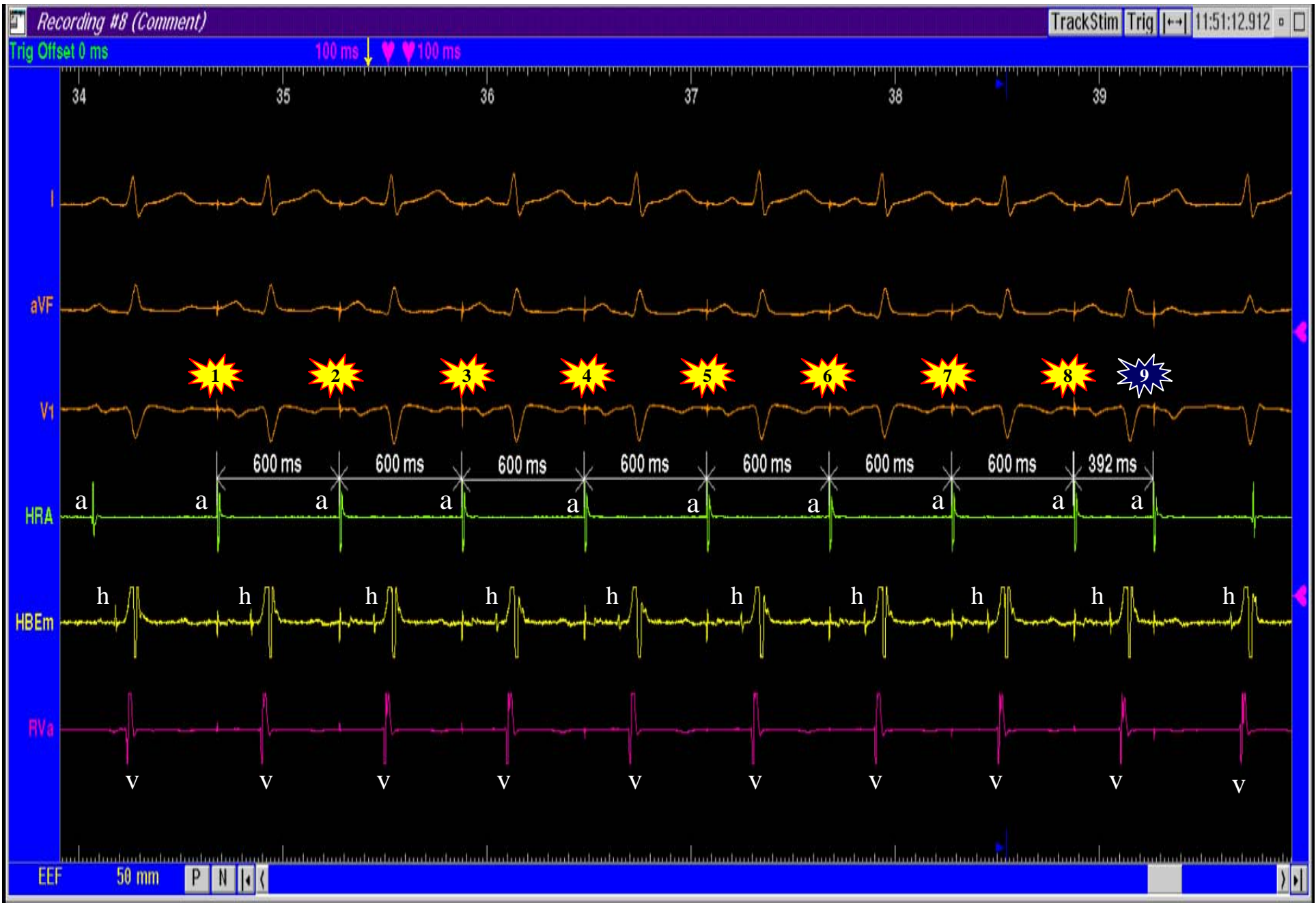Estimulación Auricular. Ciclo base a 600 ms + 1 Extraestímulo a 570 ms



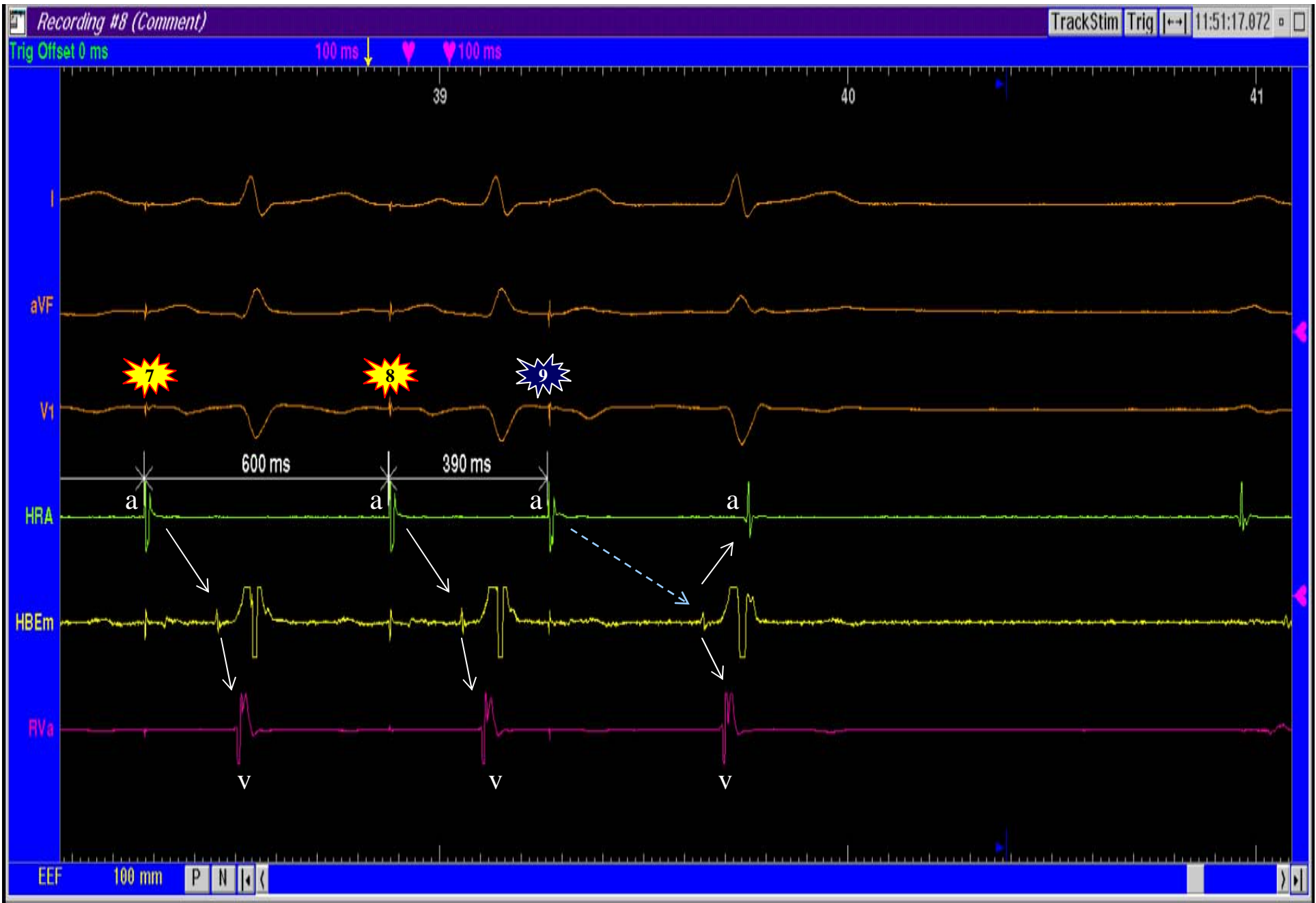
Estimulación Auricular. Ciclo base a 600 ms + 1 Extraestímulo a 570 ms

Ciclo Base a 600 ms
+ 1 Extraestímulo a 570 ms



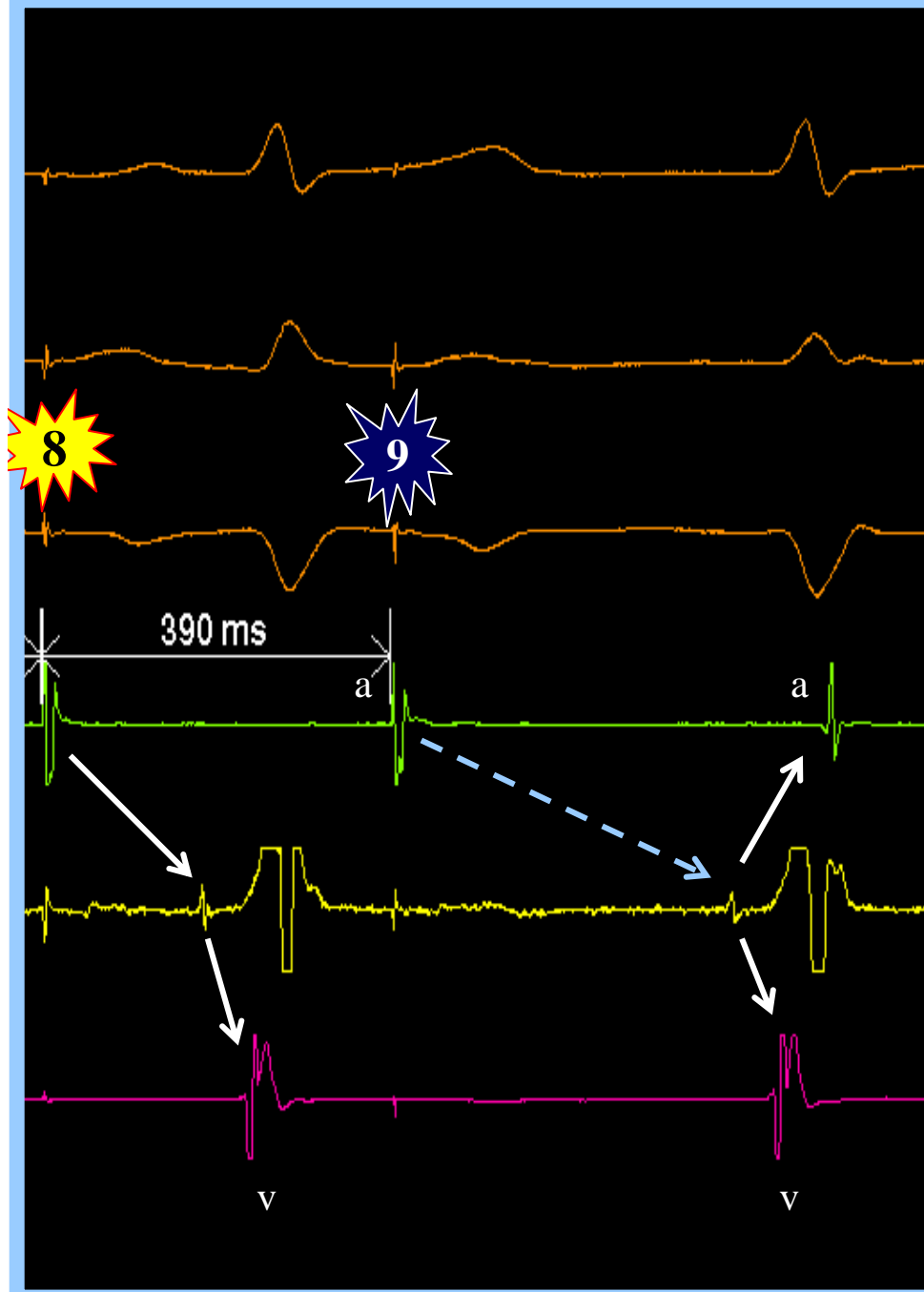


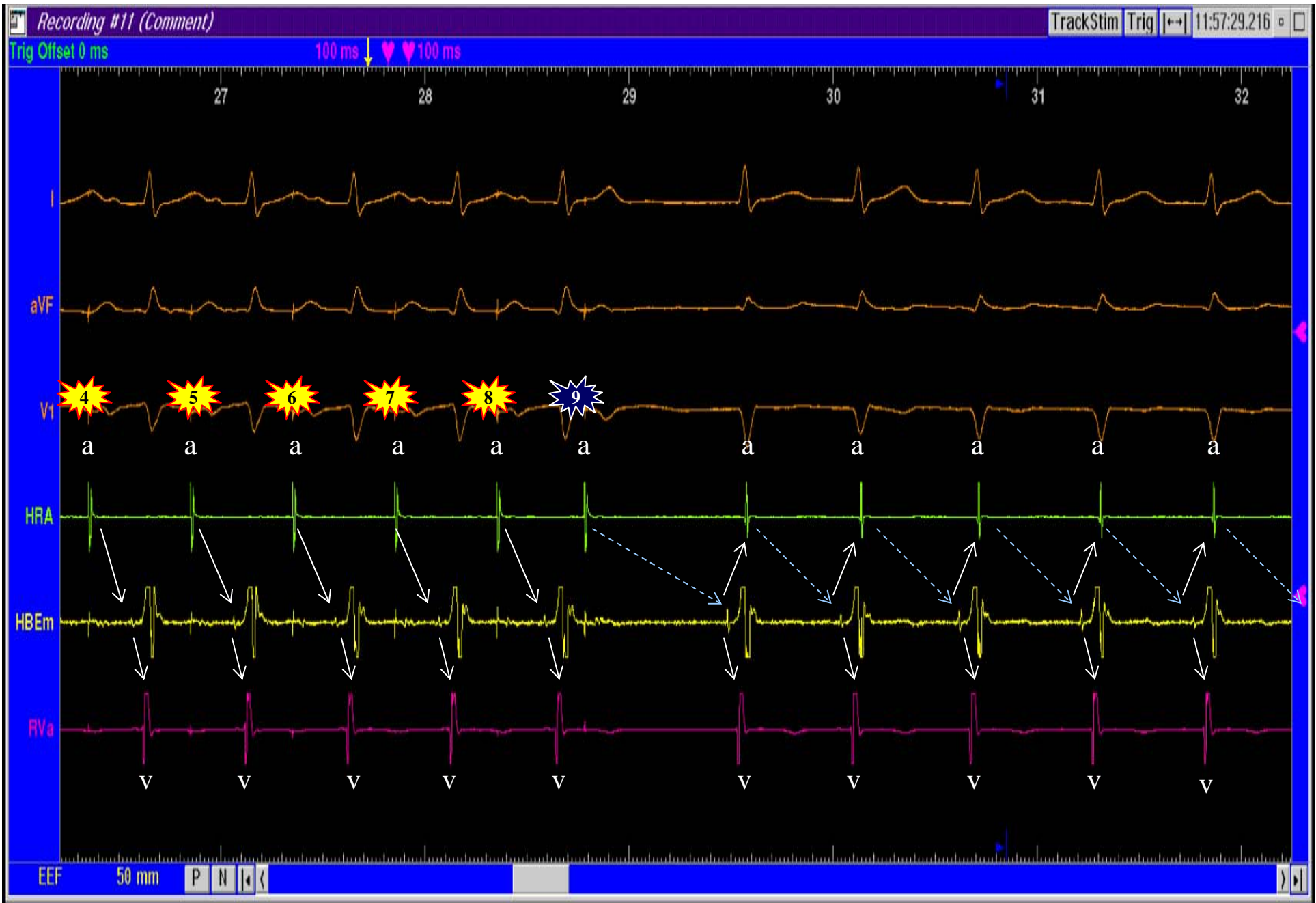
Estimulación Auricular. Ciclo base a 600 ms + 1 Extraestímulo a 390 ms



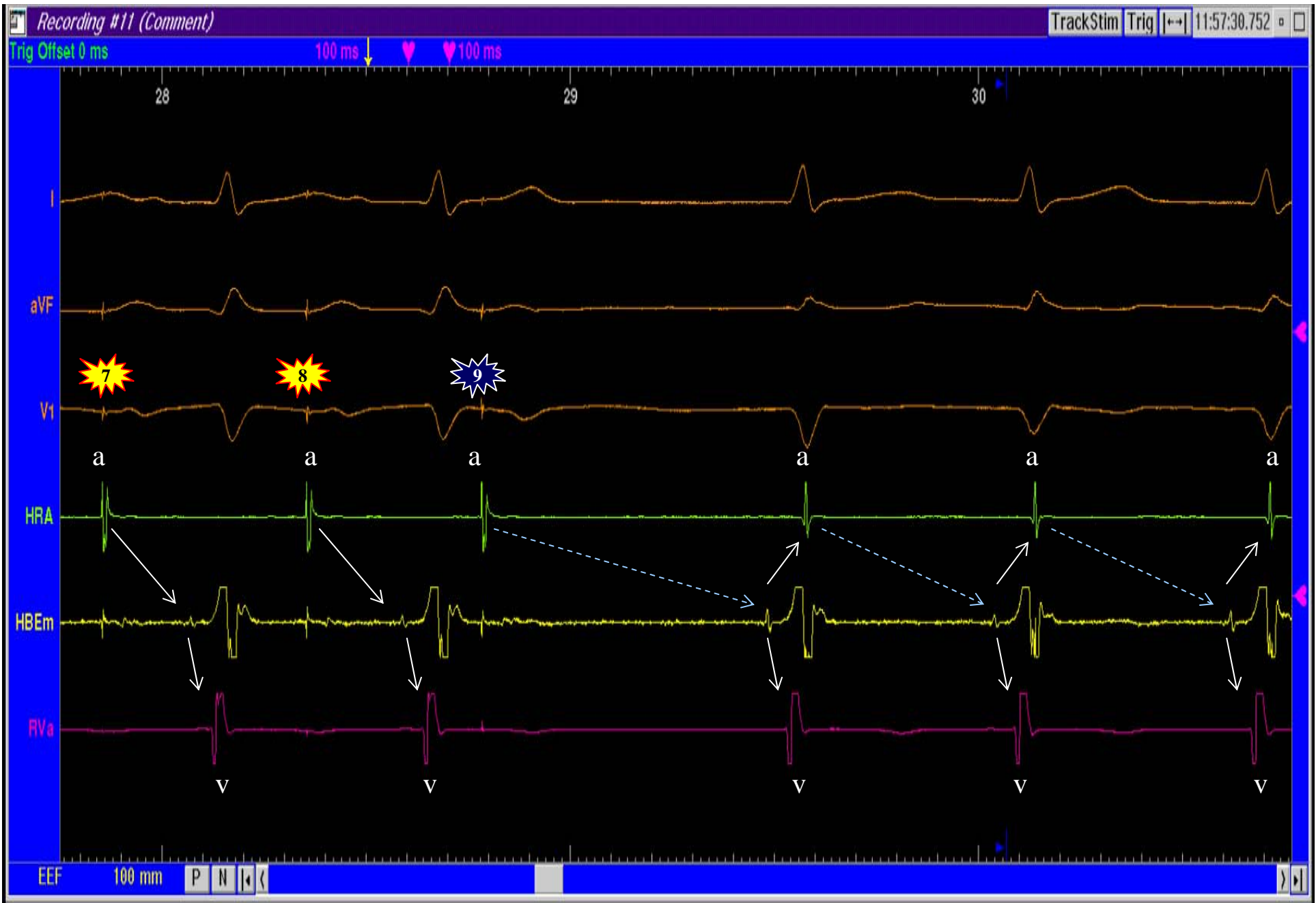
Estimulación Auricular. Ciclo base a 600 ms + 1 Extraestímulo a 390 ms

Ciclo Base a 600 ms
+ 1 Extraestímulo a 390 ms
ECO Intranodal

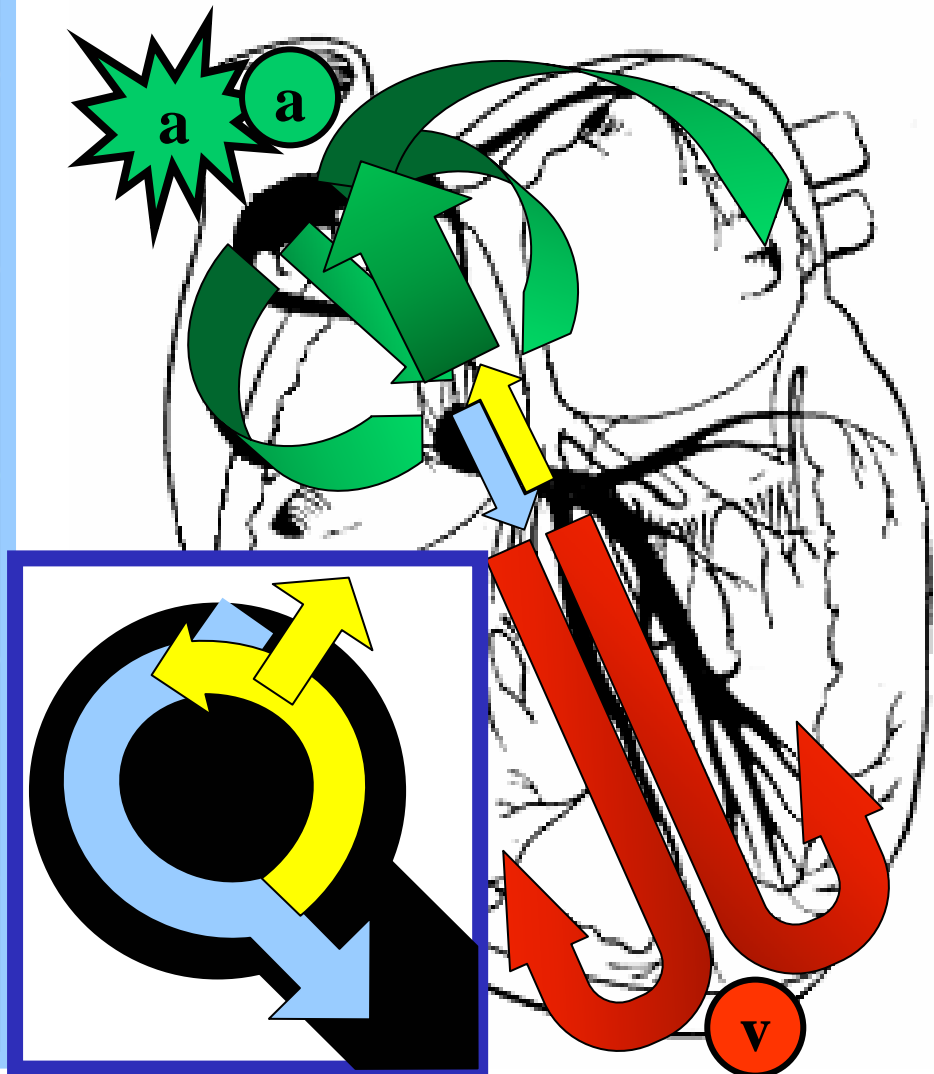
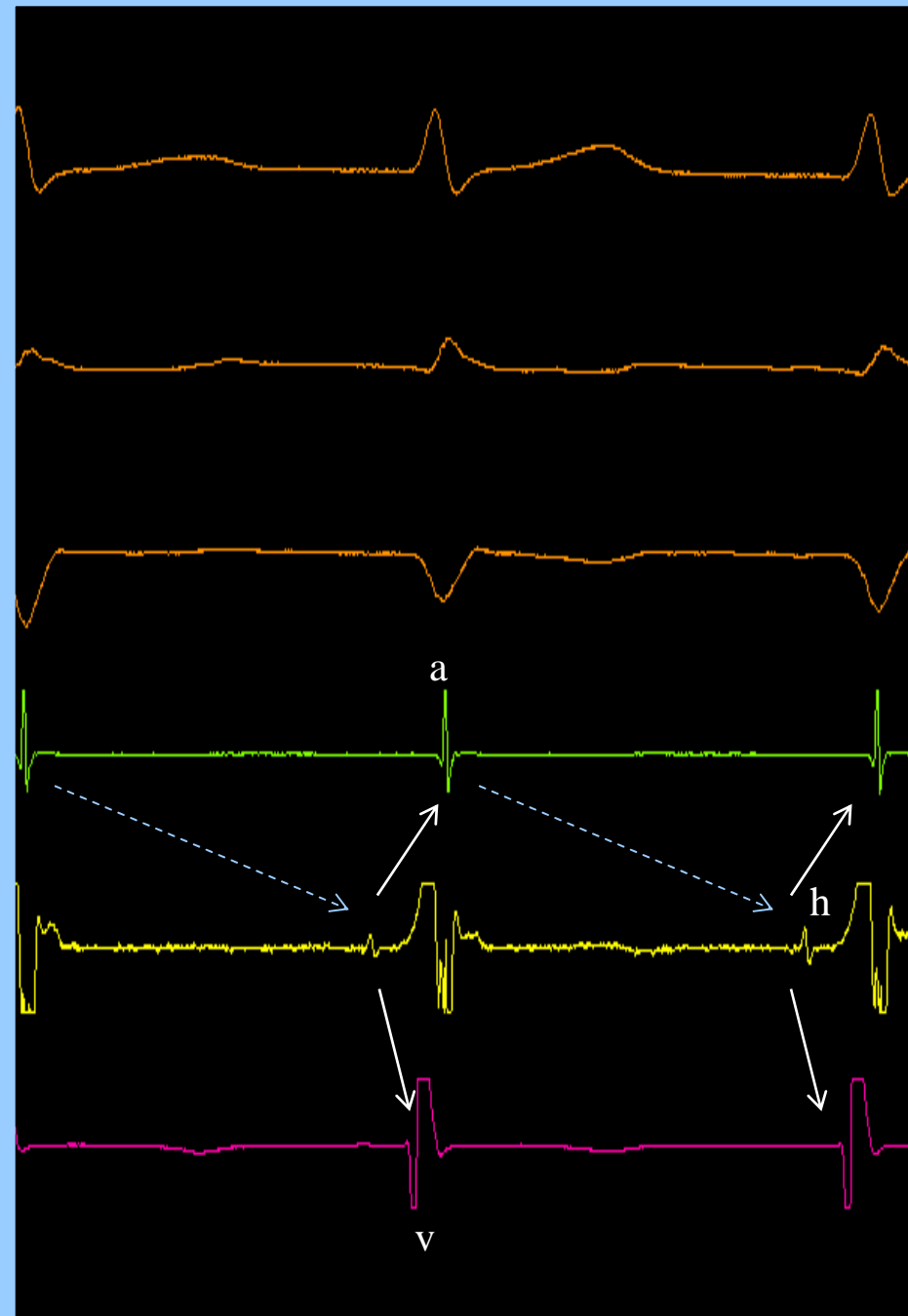


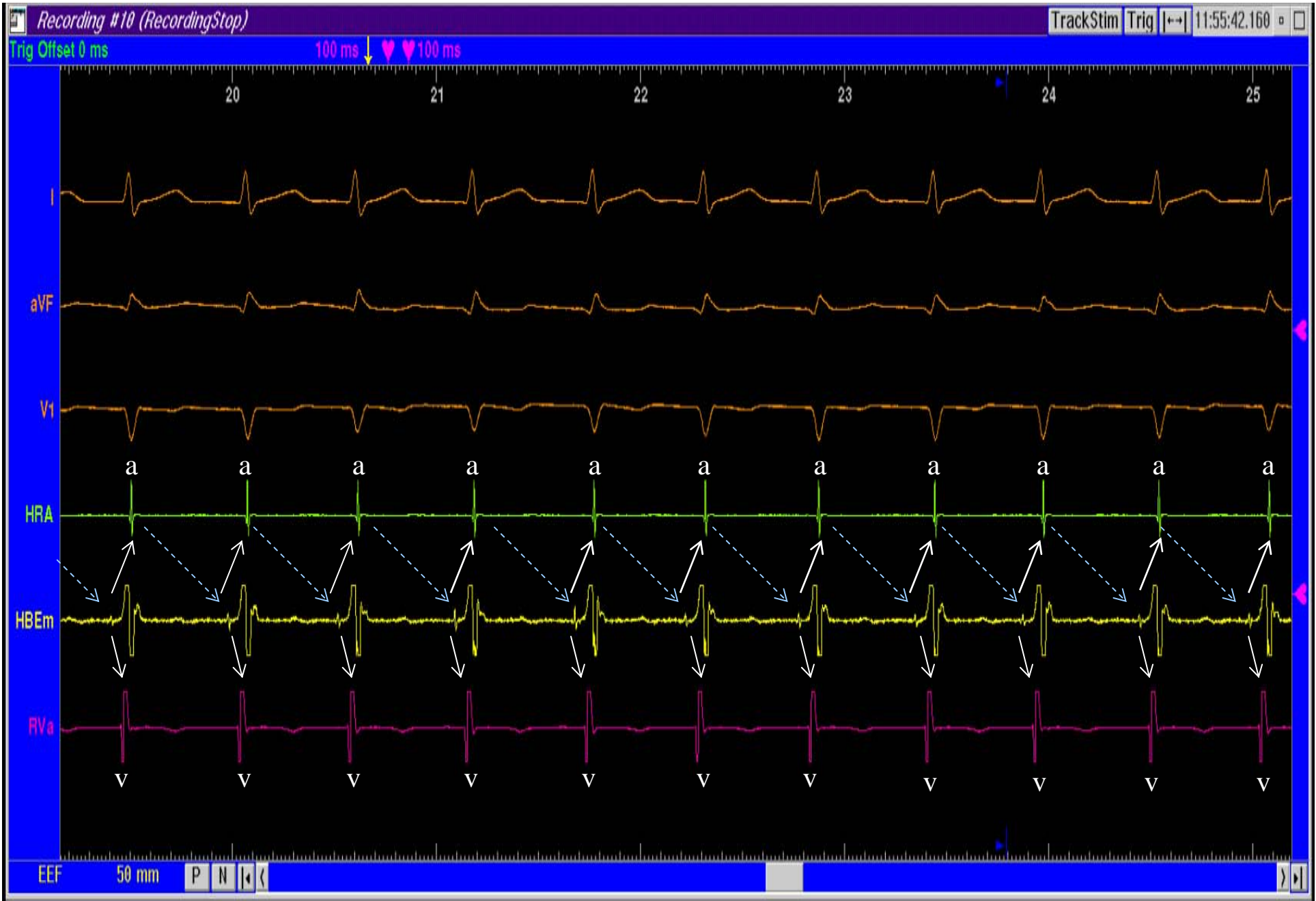

Estimulación Auricular. Ciclo base + 1 Extraestímulo = TIN

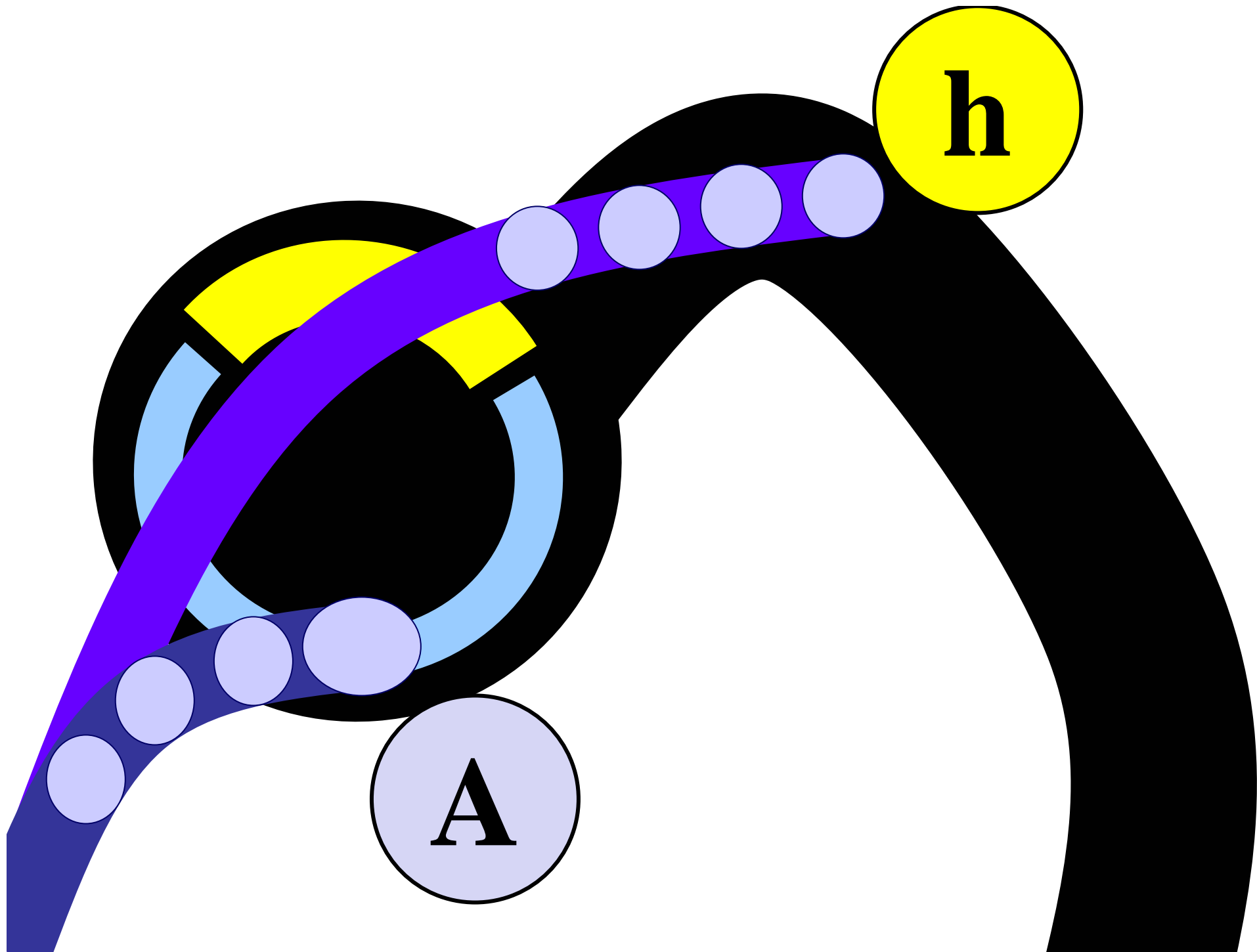


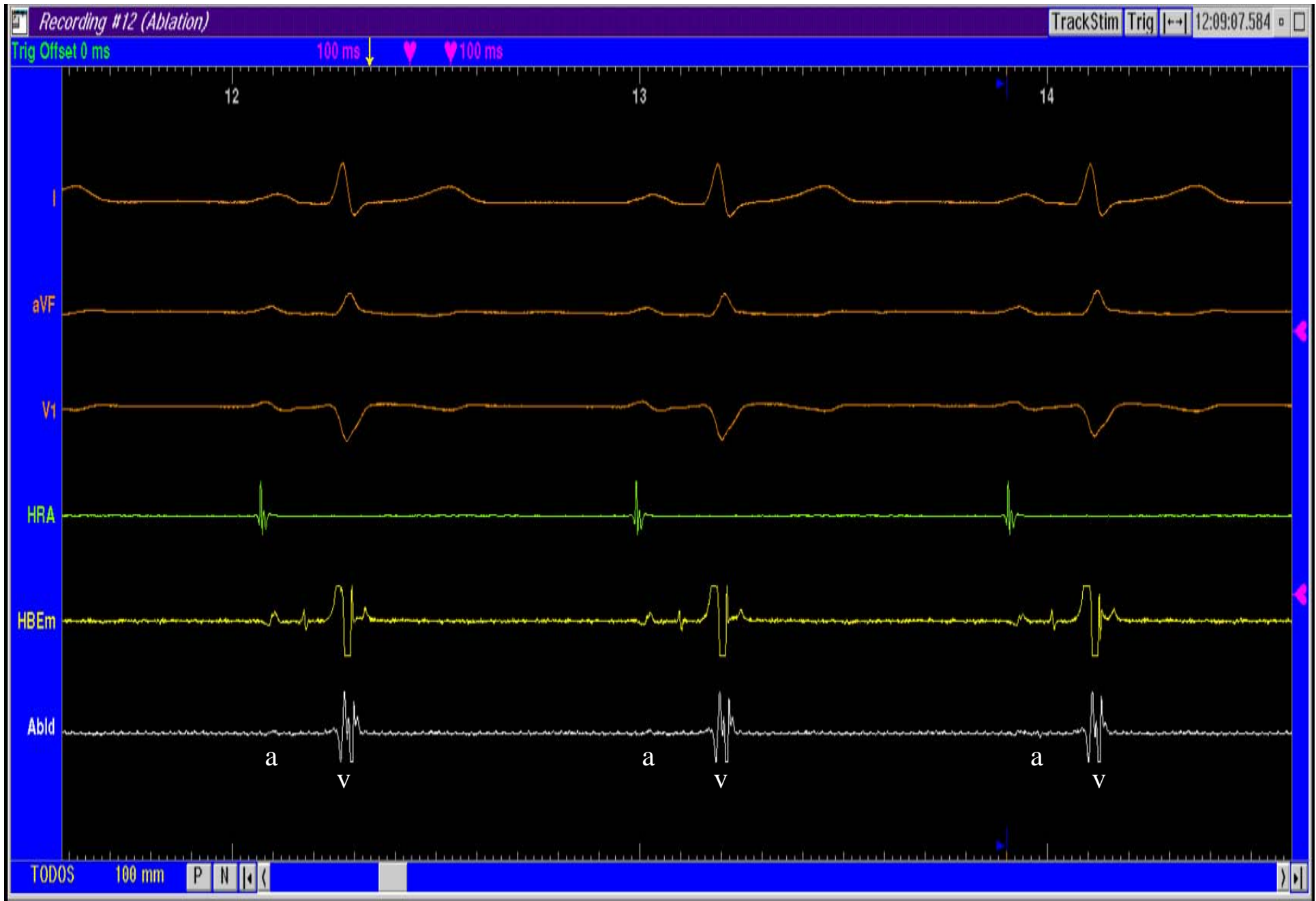
Taquicardia Intranodal



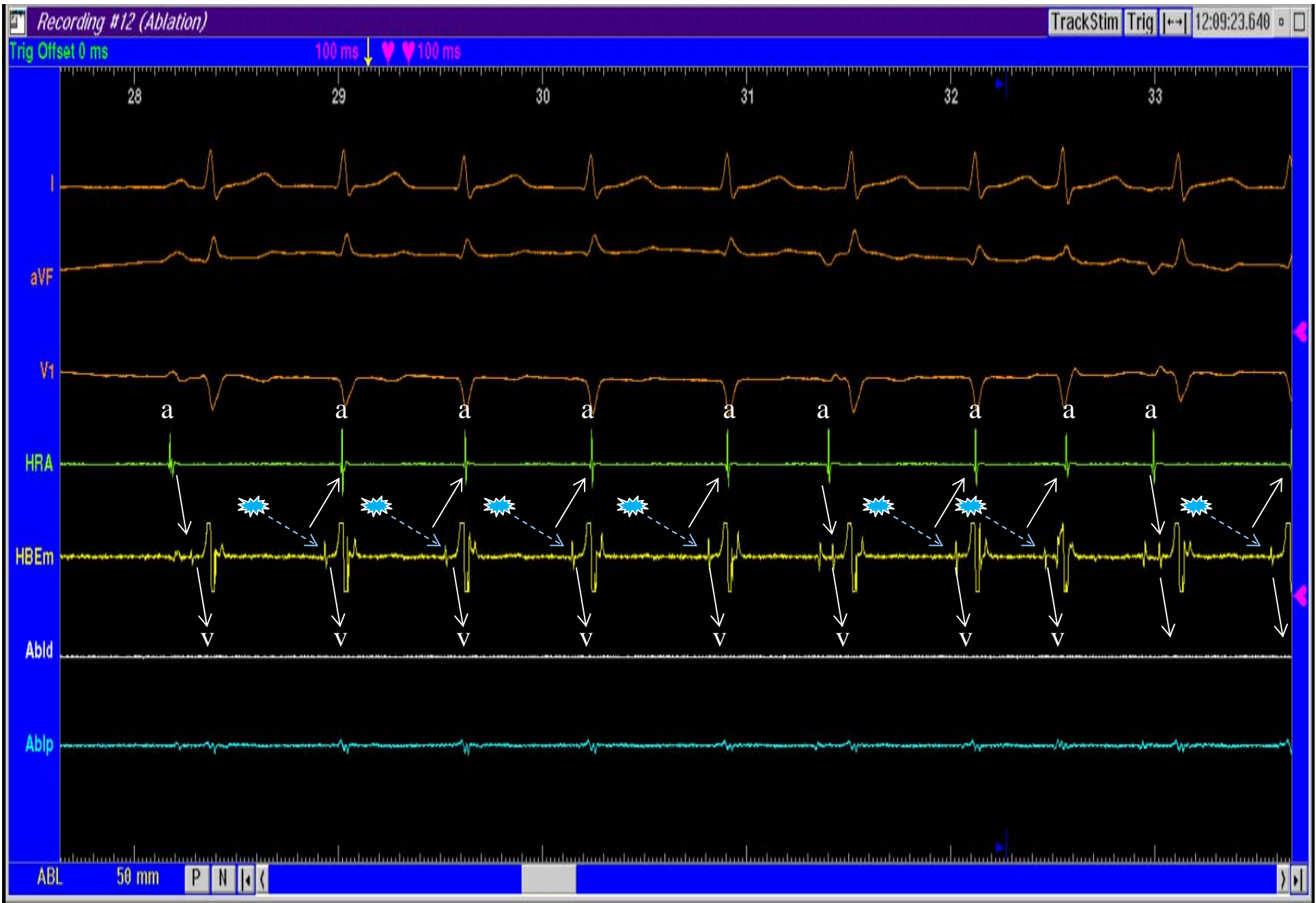

Taquicardia Intranodal

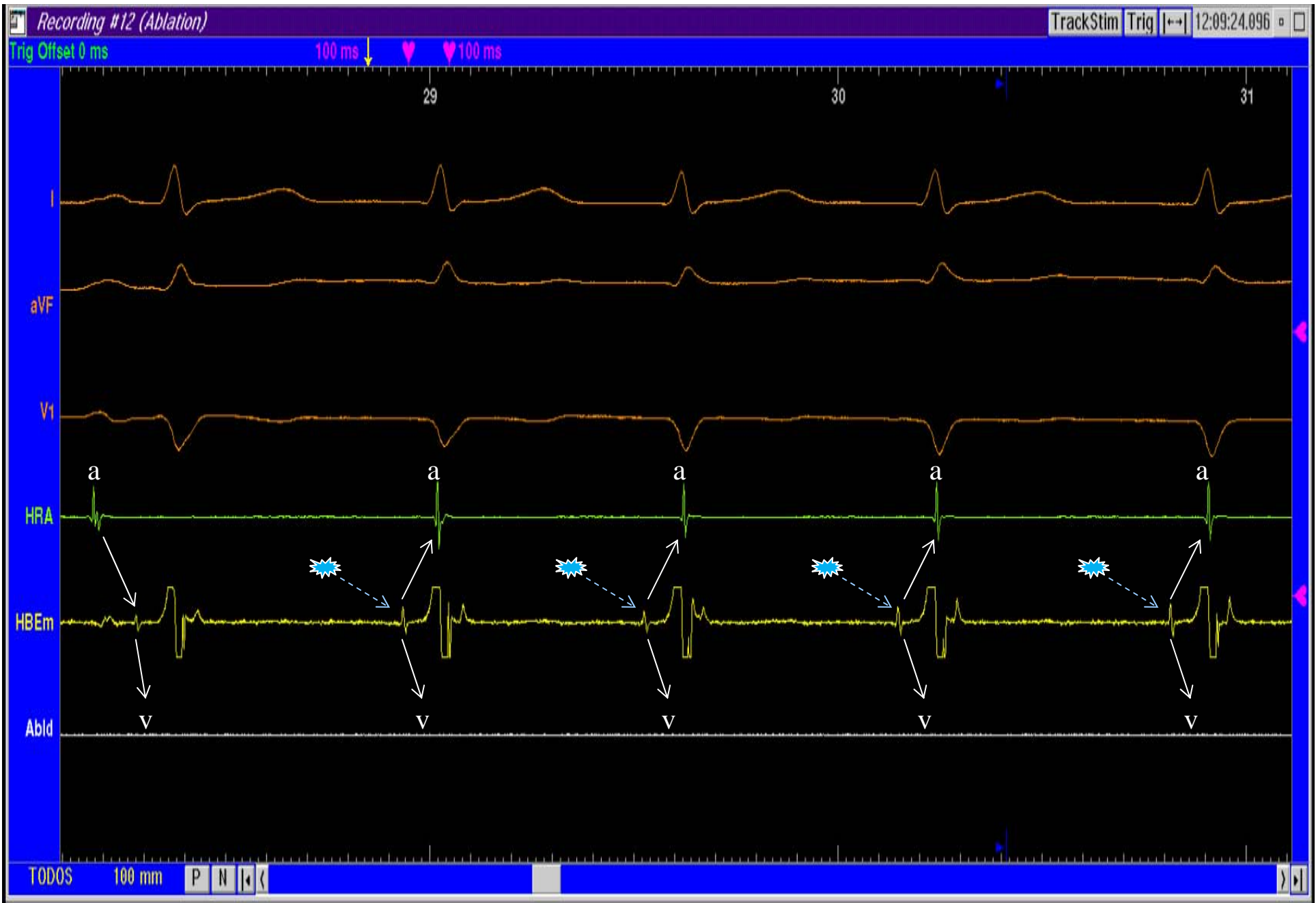




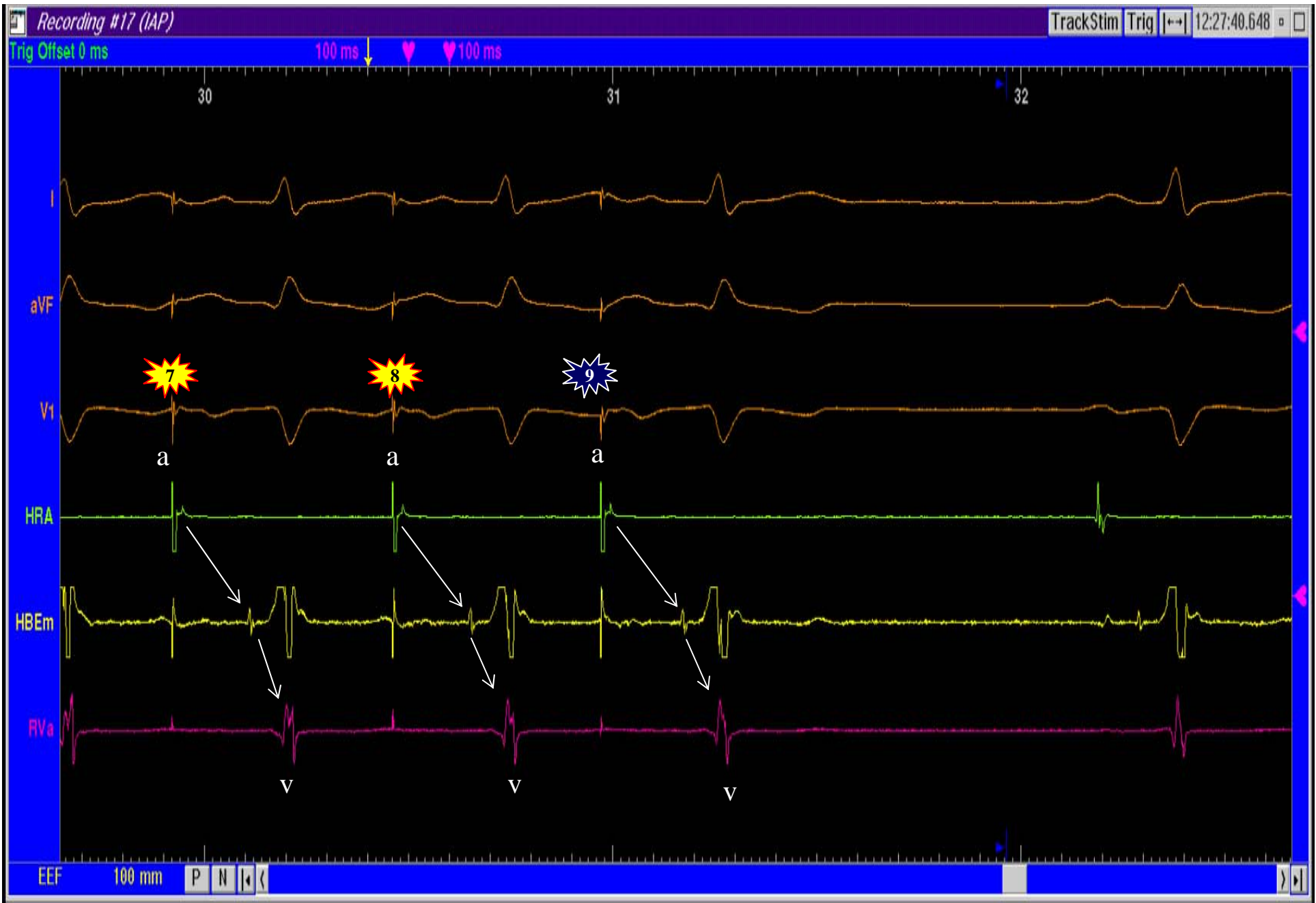
Registros de Ablación



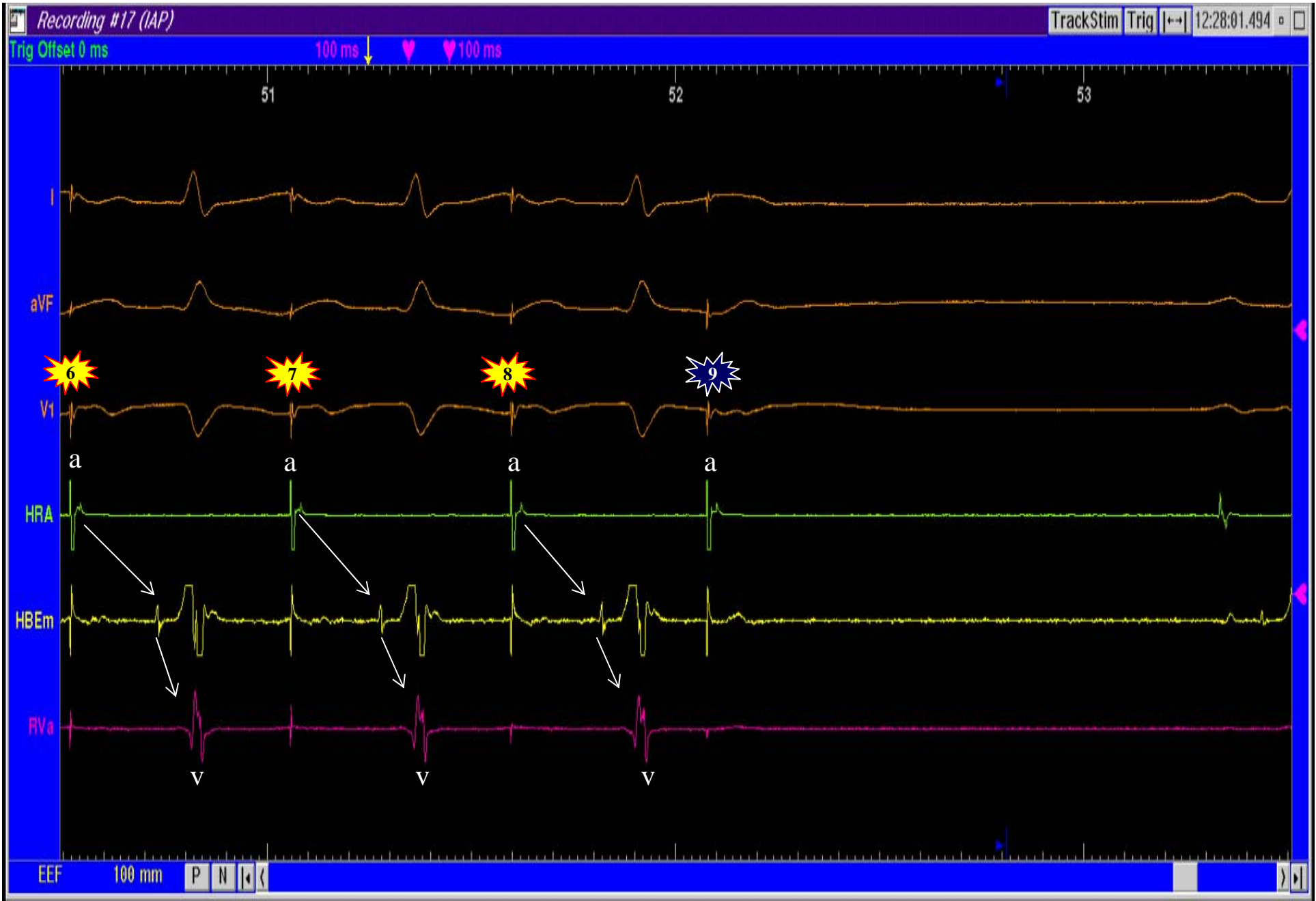
Ritmo de la Unión durante la Ablación



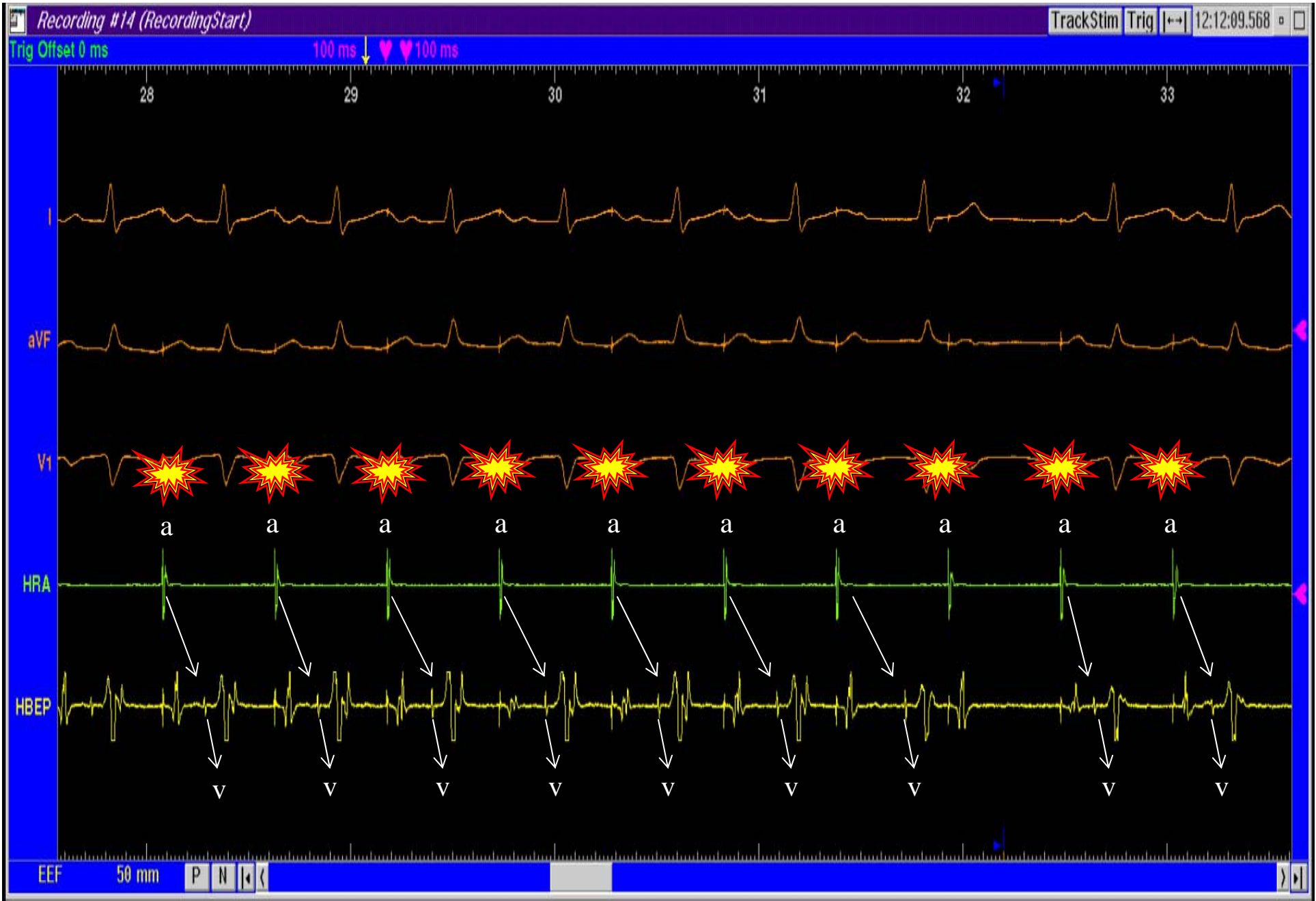
Ritmo de la Unión durante la Ablación



Estimulación Auricular. Ciclo Base + 1 Extraestímulo



Estimulación Auricular. Ciclo Base + 1 Extraestímulo



Estimulación Auricular Continua. Wenckebach